


Everything You Wanted to Know About Oral Surgery But Were Afraid To Ask!

Part 1



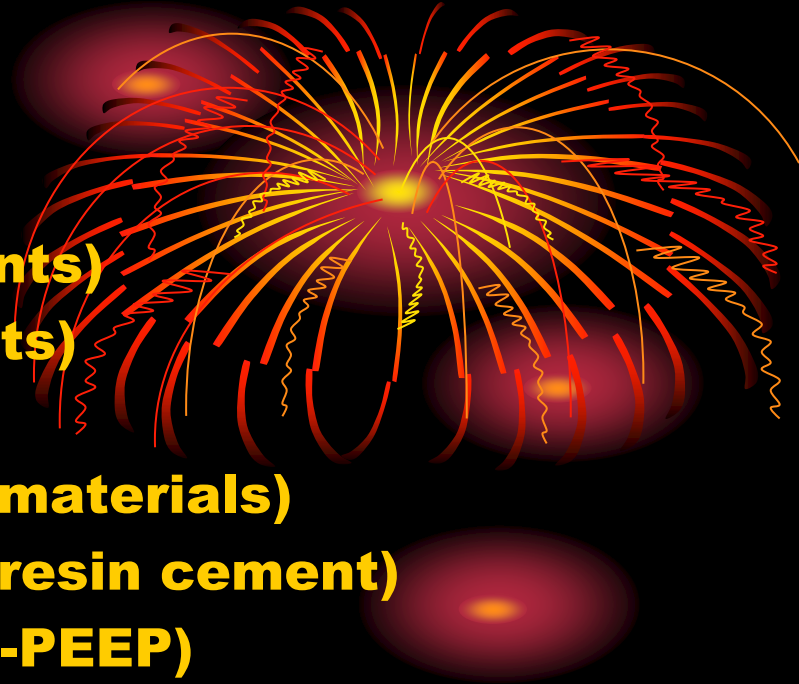
RONALD P MORRIS, DDS

Oral & Maxillo-facial Surgeon



- **Downriver Surgery Center**
- **1823 Fort, Wyandotte, MI 48192**
- **734-285-2550 DRronoms@aol.com**
- **Website: downriversurgery.com**

Sponsors

- **Keystone Dental (Tri-Max /TiLobe Maxx Implants)**
- **Implant Direct (Legacy Implants and abutments)**
- **Patterson Dental (sutures, blades, adhesives)**
- **Geistlich Biomaterials (Bio-Oss bone grafting materials)**
- **Ivoclar/Vivadent (Multilink Automix dual cure resin cement)**
- **Contour Healer (contoured healing abutments-PEEP)**
- **Palisades Dental (Impact Air 45 high speed handpieces)**
- **3M-ESPE (Polycarbonate temporary crowns)**
- **Salvin Dental Specialties (instruments)**




**It all starts with
a good anesthetic**



Oral Sedation

- **Butabarbital (Butasol)**
- **Triazolam (Halcion)**
- **Diazepam (Valium)**
- **Oral Narcotics (T#3, Vicodin, Norco)**
- **Oral Fentanyl (Actiq lozenge)**
- **(Nitrous Oxide sedation)**



Butisol Oral Dosing Guidelines

Approx. Weight In Pounds	Approx. Age	Dose in Ounces
30-40	2-3	$\frac{1}{4}$ - $\frac{1}{3}$
40-50	3-5	$\frac{1}{3}$ - $\frac{1}{2}$
50-70	5-8	$\frac{1}{2}$ - $\frac{2}{3}$
70-100	8-12	$\frac{2}{3}$ - 1
100-150	12-18	1 - $1\frac{1}{2}$
150-200	18+UP	$1\frac{1}{2}$ - 2

On an empty stomach is effective in about 10 minutes. Last 3-4 hours.
If dose isn't adequate after 30 minutes repeat $\frac{1}{2}$ of original dose
Available through at PSI 1-800-998-8558



Topical Anesthetics:

20% Standard Benzocaine

Rx Topical (pharmacy formulated)

10% lidocaine



2.5% prilocaine


10% tetracaine

TAC Alternate Gel (TAC 20)

Lidocaine 20%, Tetracaine 4%,

Phenylephrine 2%






Local Anesthetics

Review of common Local Anesthetics

- **Short Duration**
- **Moderate Duration**
- **Long Duration**
- **“Permanent”**



Local Anesthetic	Trade Names	Max dose in Adult	Max dose in child (est 15kg/33lbs)	Duration of action	PRC	Metabisulfite	drug interactions
Lidocaine 2% w/epi	Xylocaine, Octocaine Lingospan, Alphacaine	7mg/kg 500mg max 13 cartridges	4-7mg/kg 105mg max 2.9 cartridges	60-190 minutes	B	yes	increased BP, Beta blockers tricyclic antidepressants halothane, cocaine
Mepivacaine 3% plain	Carbocaine, Polocaine, Scandonest, Isocaine	6.6mg/kg 400mg max 7 cartridges	same as adult 1.8 cartridges	25-160 minutes	C	no	none known
Mepivacaine 2% w/ levonordefrin	same as above with Neo-Cobefrin	6.6mg/kg 400mg max 11 cartridges	same as adult	50-185 minutes	C	yes	same as epi no tricyclics at all
Prilocaine 4% plain	Citanest	8mg/kg 400mg max 8 cartridges	same as adult 1 cartridge	20-190 minutes	B	no	Methemoglobinemia
Prilocaine 4% w/epi 1:200,000	Citanest Forte	8mg/kg 400mg max 8 cartridges	same as adult 1 cartridge	40-220 minutes	B	yes	Same as Epi Methemoglobinemia
Articaine 4% w/epi 1:200,000 1:100,000	Septocaine, Septanest N Septanest SP Ultracaine forte	7mg/kg 500mg max 7 cartridges	5mg/kg 3 cartridges	60-230 minutes	C	yes	Same as Epi Methemoglobinemia
Bupivacaine 0.5% w/epi 1:100,000	Marcaine	2mg/kg 200mg max 10 cartridges	same as adult not generally rec	40-440 minutes	C	yes	Same as Epi
Etidocaine 1.5% w/epi 1:200,000	Duranest	8mg/kg 400mg max	NA	40-440	B	yes	Same as Epi
Prilocaine 3% w/felypressin 1:100,000	3% Citanest Dental w/Octapressin	8mg/kg 400mg max 8 cartridges	same as adult 1.2 cartridges	40-220 minutes	B	no	Methemoglobinemia less stimulating than Epi no ischaemia at site!



FDA Use-in-Pregnancy Ratings

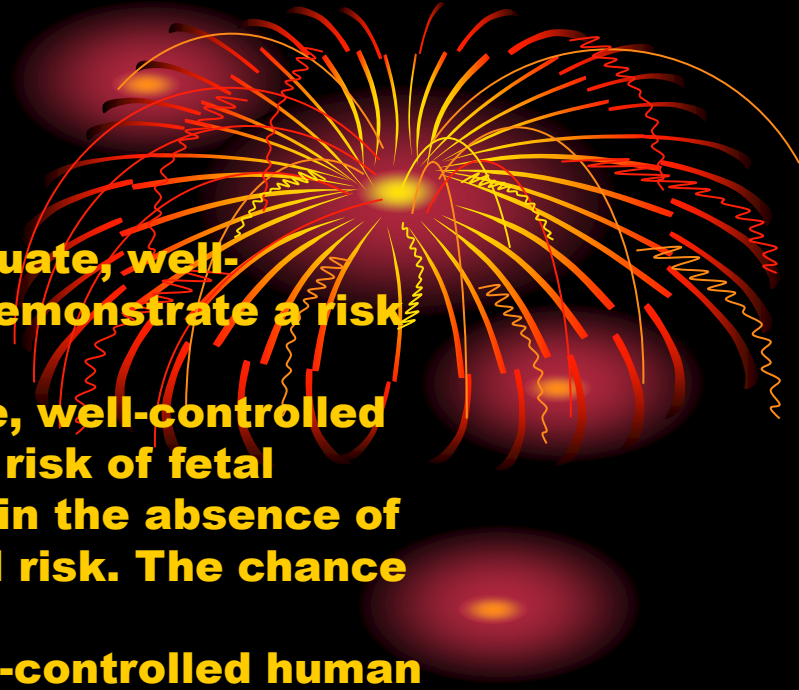
A CONTROLLED STUDIES SHOW NO RISK. Adequate, well-controlled studies in pregnant women have failed to demonstrate a risk to the fetus in any trimester of pregnancy.

B NO EVIDENCE OF RISK IN HUMANS. Adequate, well-controlled studies in pregnant women have not shown increased risk of fetal abnormalities despite adverse findings in animals, or, in the absence of adequate human studies, animal studies show no fetal risk. The chance of fetal harm is remote, but remains a possibility.

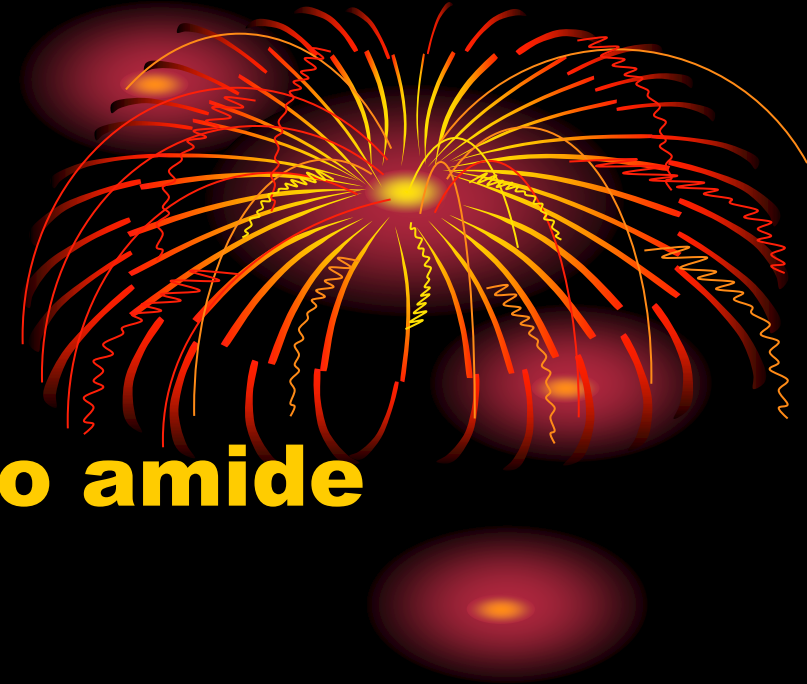
C RISK CANNOT BE RULED OUT. Adequate, well-controlled human studies are lacking, and animal studies have shown a risk to the fetus or are lacking as well. There is a chance of fetal harm if the drug is administered during pregnancy; but the potential benefits may outweigh the potential risks.

D POSITIVE EVIDENCE OF RISK. Studies in humans, or investigational or post-marketing data, have demonstrated fetal risk. Nevertheless, potential benefits from the use of the drug may outweigh the potential risk. For example, the drug may be acceptable if needed in a life-threatening situation or serious disease for which safer drugs cannot be used or are ineffective.

X CONTRAINDICATED IN PREGNANCY. Studies in animals or humans, or investigational or post-marketing reports, have demonstrated positive evidence of fetal abnormalities or risks which clearly outweighs any possible benefit to the patient.



Allergic reactions



- **True reactions extremely rare to amide local anesthetics**
- **Most responses are Vaso-Vagal syncope, I.E. – fainting**
- **Recommend skin testing**
- **Consider cardiac 2% lidocaine**
- **Consider Benadryl for injection**

Local anesthetic choice for various procedures



- **Routine operative (less than 1 hour, non bloody) – LA with NO vasoconstrictor, such as carbocaine or prilocaine plain**
- **Complex operative, C&B (more than 1 hour, and bloody) – LA with vasoconstrictor, such as 2% lidocaine w/ 1:100,000epi**

Local anesthetic choice for various procedures

- **Long procedures or procedures with post operative pain – Long duration LA w/ vasoconstrictor, such as 0.5% marcaine w/ epi or Exparel (liposome encapsulated marcaine/)**




“permanent” nerve block local anesthetics



- **Denatured alcohol**
- **Glycerin**
- **Botox - botulinum toxin A**
- **Myobloc – botulinum toxin B**

- **All these agents generally provide 4-12 months of parathesia**

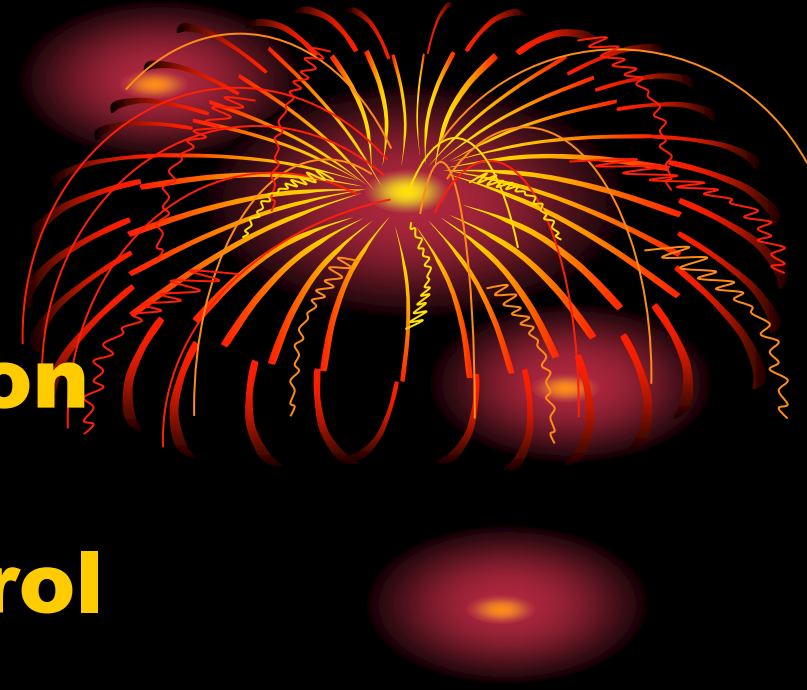Local anesthetic adjuncts



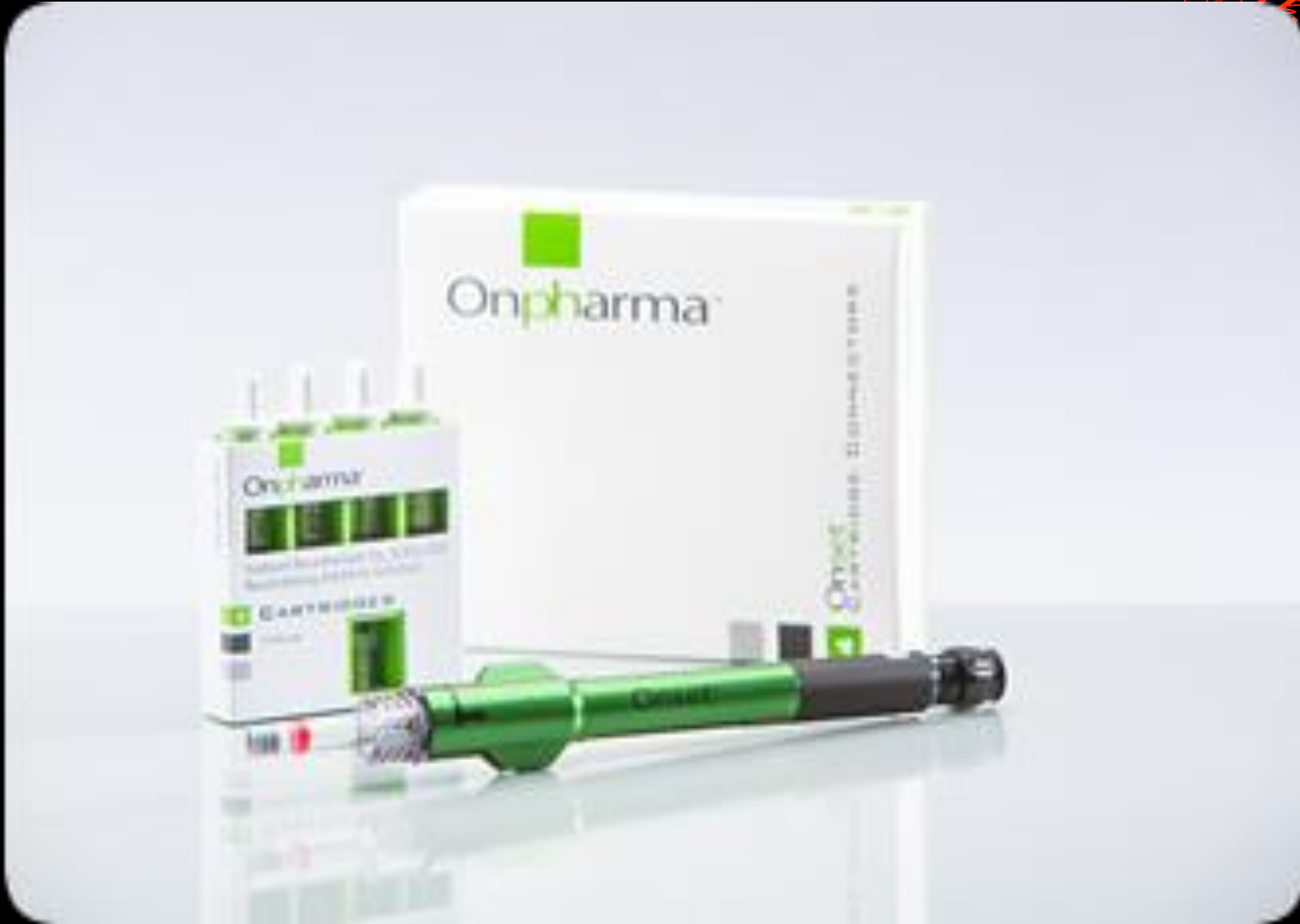
- **OraVerse-reversal agent**
- **Intra Osseous injection Stabident, X-tip, & Hypo systems**
- **TENS system (transcutaneous electrical nerve stimulator)**
- **Palatal anesthesia device (Salvin)**
- **MadaJet *XL Dental***



Local anesthetic adjuncts

- **Pressure controlled injection devices – the “Wand”, (Milestone); “Comfort Control Syringe”, (Midwest)**
- **PDL injectors – “N-Tralig” “Numbee” syringe/needle**
- **Hypnosis**
- **Pre-op sedatives – nitrous oxide, Valium, Xanax, butabarbital**
- **Buffering systems- NaHCO_3**

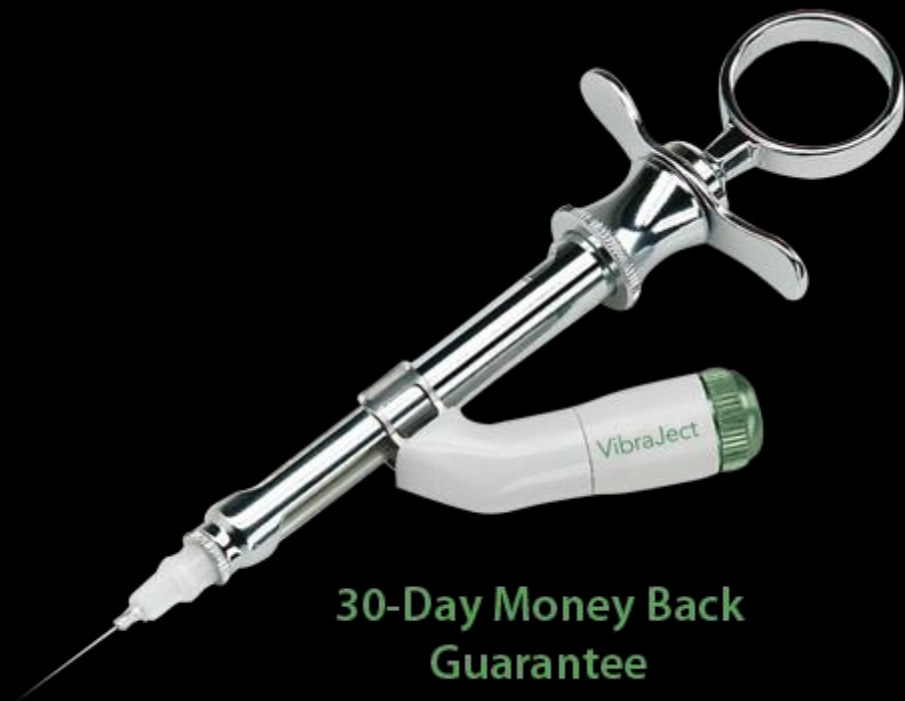

Buffering pen






VibraJect



30-Day Money Back
Guarantee



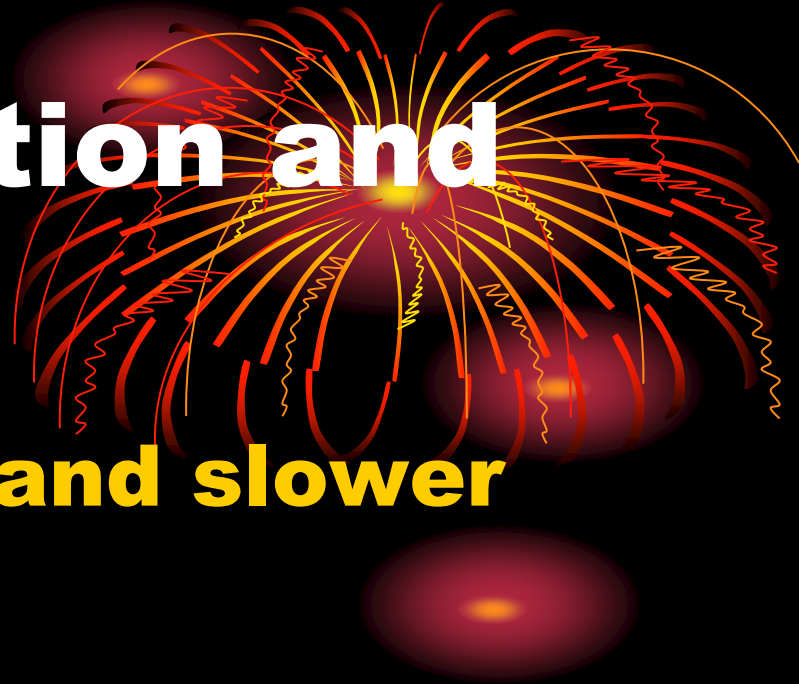
Local anesthesia adjuncts



- **Active motion of the needle or soft tissue**
- **Wide area stimulation with pressure prior to injection, works by the gate control theory of pain and allows space for the fluid to expand**
- **30 gauge needle for most blocks**

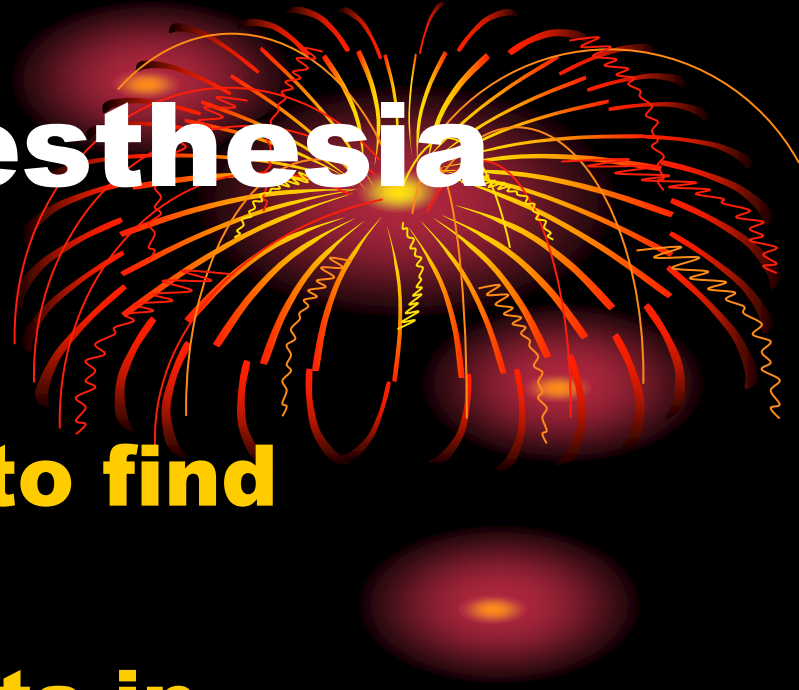Keys to a painless injection and a happy patient!

- **Go Slow! One drop per second (and slower if the patient can feel it)**
- **Warm the carpules**
- **Inject local ahead of the needle advancing**
- **Avoid “sawing” the needle**



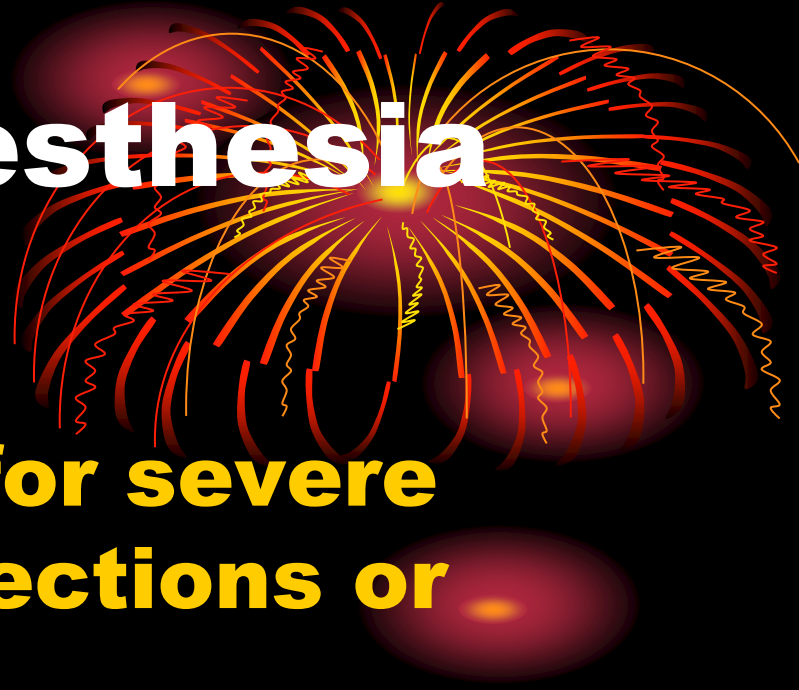Special use of Local anesthesia injections

- **For diagnostic injections to find source of pain**
- **For control of trigger points in various neuralgias, both diagnostic and therapeutic**
- **Relief of pain and breaking of adhesions and releasing closed lock internal derangements in the TMJ**



Special use of Local anesthesia injections

- **Extra – oral mandibular blocks for severe trismus secondary to dental infections or trauma**



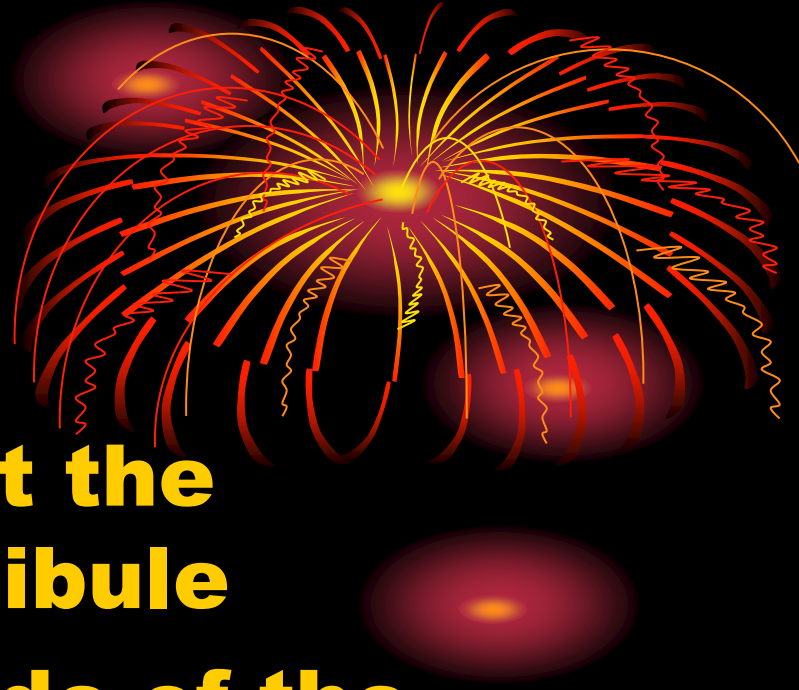Maxillary Blocks V2

- **PSA-posterior superior alveolar**
- **MSA-middle superior alveolar**
- **ASA-anterior superior alveolar**

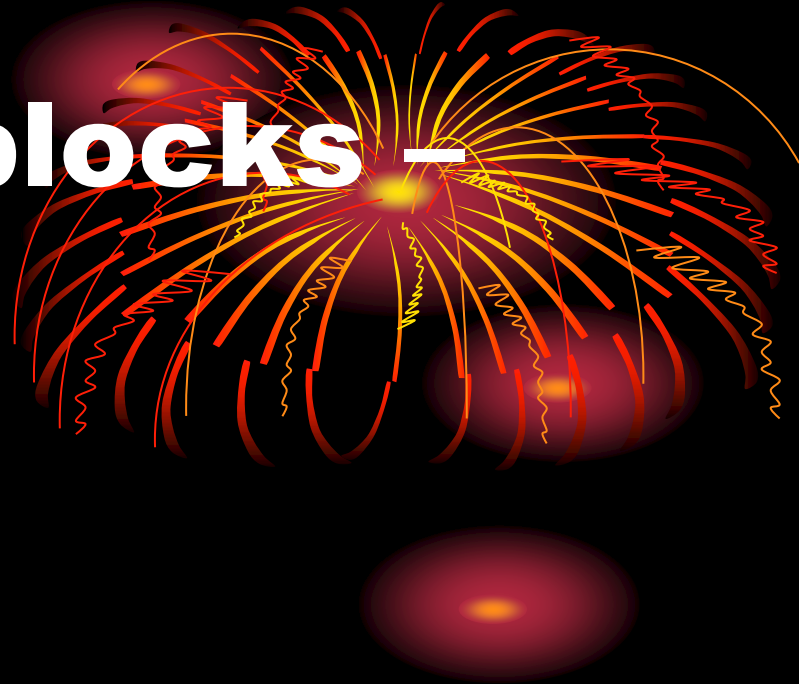


Maxillary infiltration

- **Anesthesia injected generally at the approximate apex/depth of vestibule**
- **Generally one tooth on either side of the tooth being worked on**
- **Provides hemostasis with LA/epi injection into gingiva**



High division Maxillary blocks – complete V2

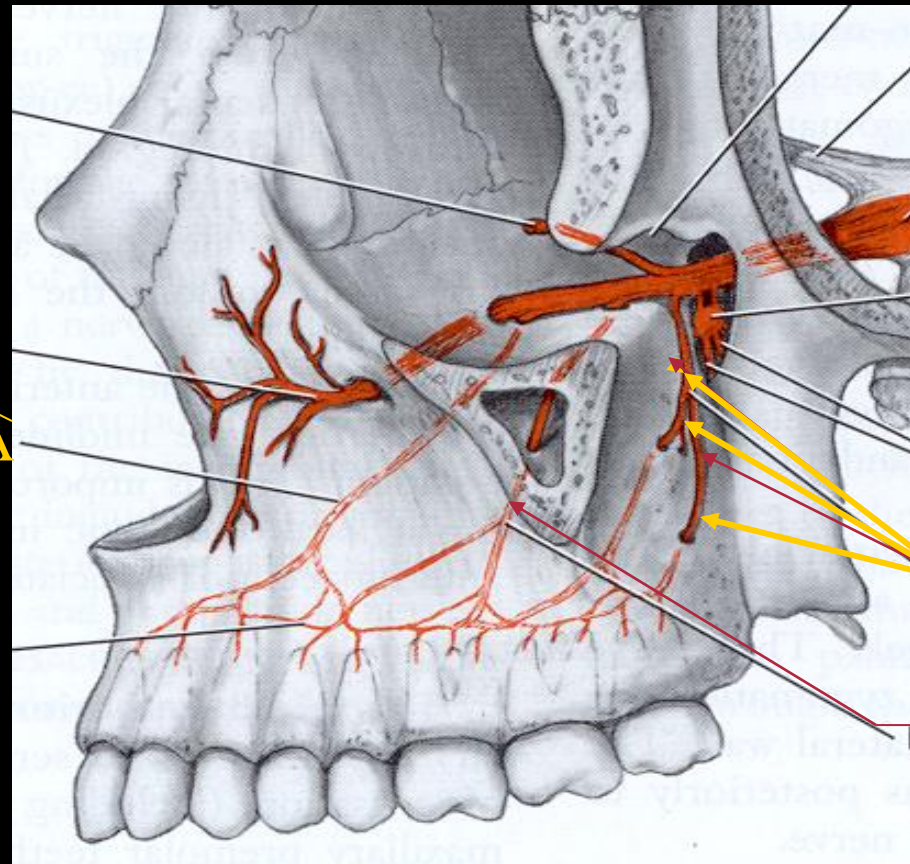


- **Infraorbital – intraoral**
- **Infraorbital – extraoral**
- **Pterygo-palatine fossa – from Greater palatine foramen**
- **Pterygo-palatine fossa – from lateral approach through the Pterygo-maxillary fissure (a deep PSA) easier with 27ga**

Posterior Superior Alveolar Nerve (PSA)



Posterior
superior
alveolar nerve
is a little
different.

ASA



PSA

MSA

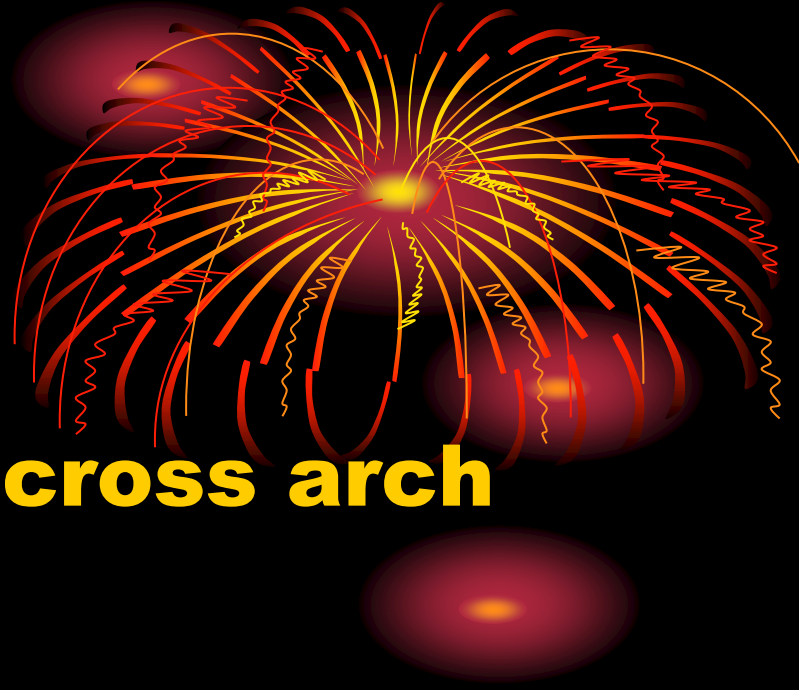


Common reasons for failed blocks - Maxilla



- **Bone very thick – as in bruxers, clenchers, and exostosis/tori formation, and anterior teeth**
- **Palatal innervation**
- **Infection and inflammation**
- **Contra-lateral or co-innervation**

Inferior Alveolar Blocks



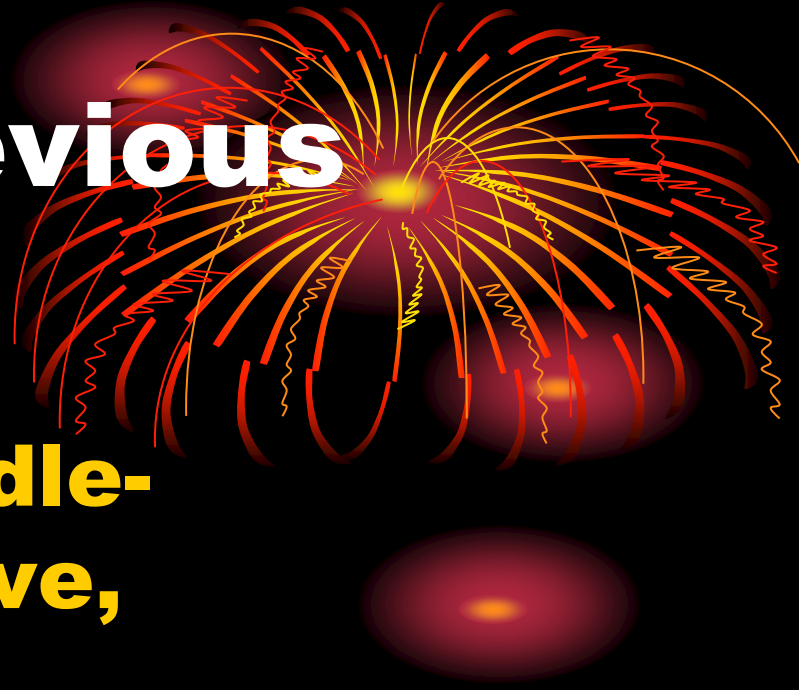- **Traditional Halstead approach (cross arch technique)**
- **Gow-Gates**
- **Akinosi**
- **ART- Anterior Ramus Technique**
- **“RPM”™ direct anatomical approach**

This is the General Rule IAN Block:



- **In general, in order to achieve profound pulpal anesthesia of the lower teeth, the inferior alveolar nerve must be blocked.**
- **There are exceptions, however.**


Problems/Failures of previous techniques


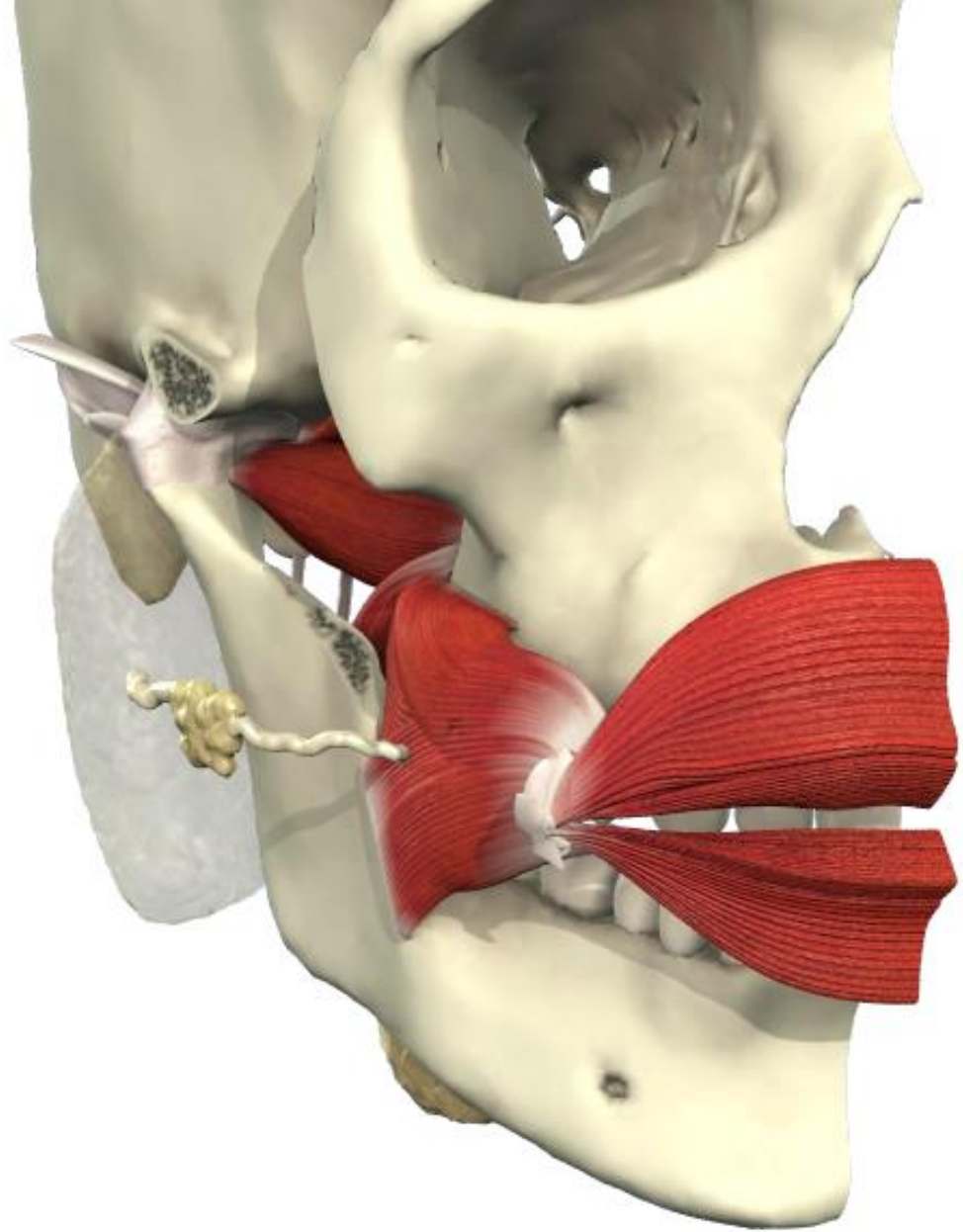



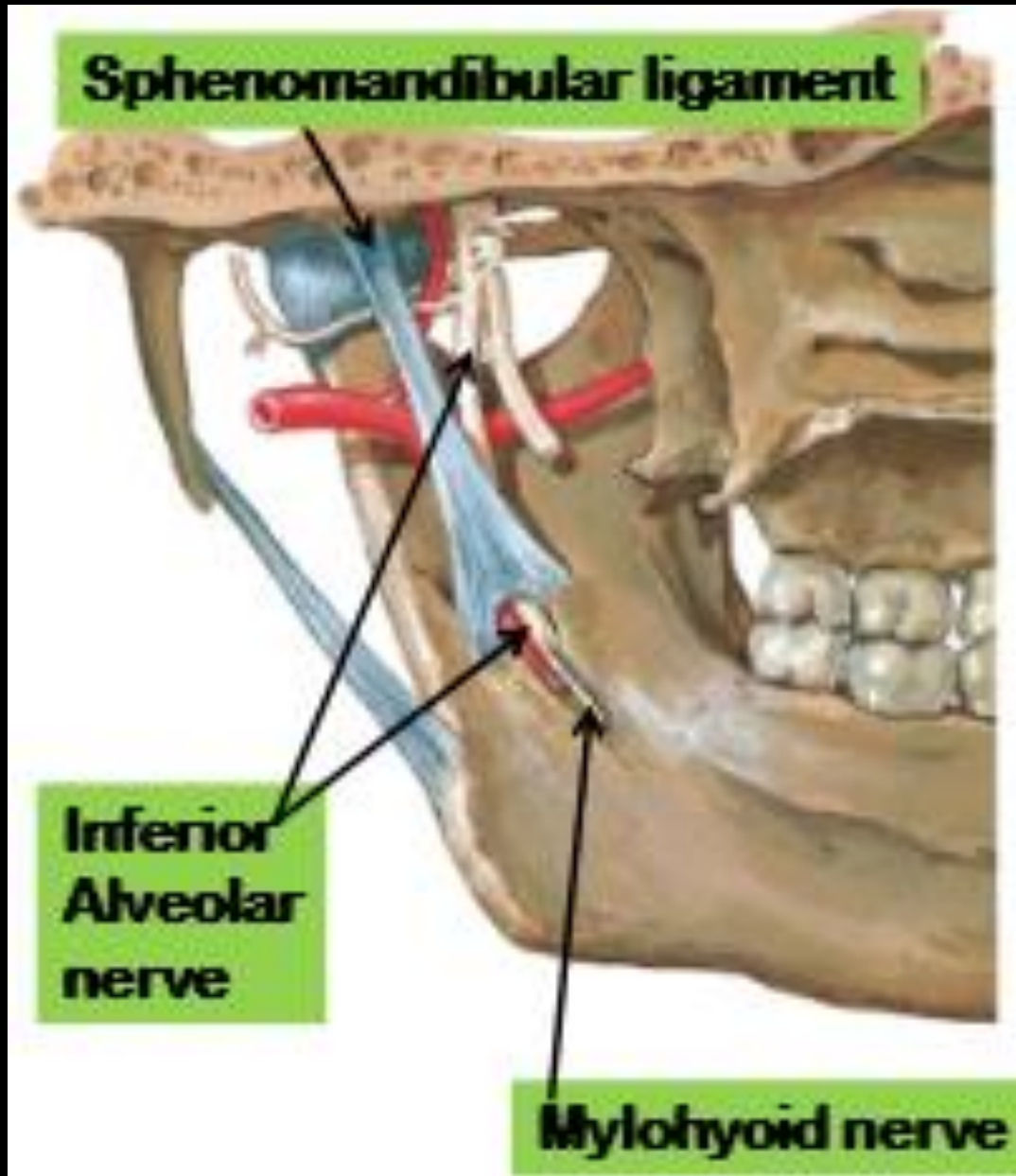
- **Must use a 27 ga long needle-
more risk of trauma to nerve,
artery, and veins**
- **Based on soft tissue landmarks-
which vary greatly and in many
cases are not present**
- **High probability of intra-
muscular injection--post op pain**

“RPM”™ Technique

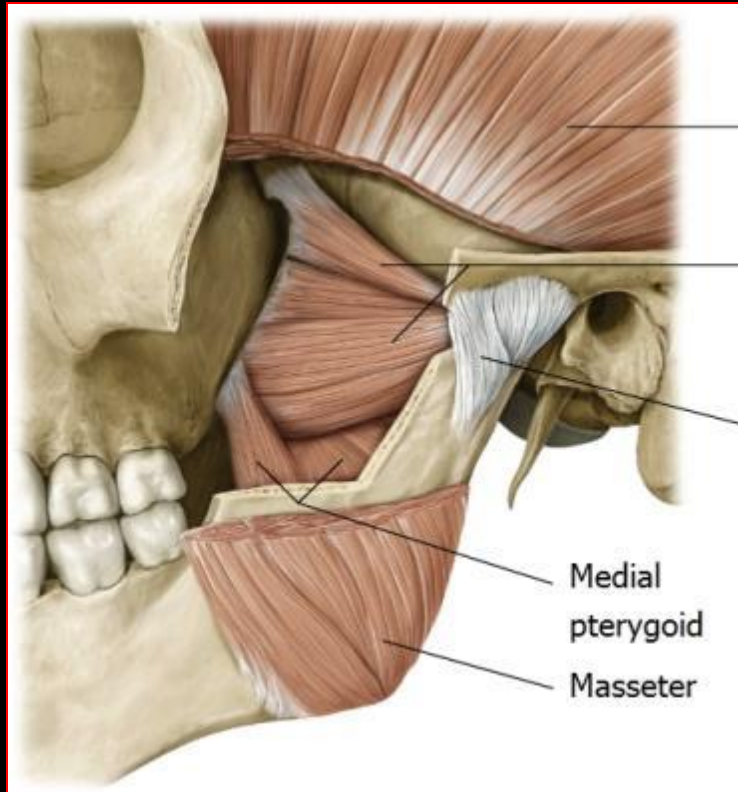
- **Orient free hand on anterior border, centered on the Coronoid notch (deepest portion) and posterior ramus**
- **Syringe and needle align parallel to this lateral plane and enter straight in**
- **Redirect as needed to get around anterior border of ramus**



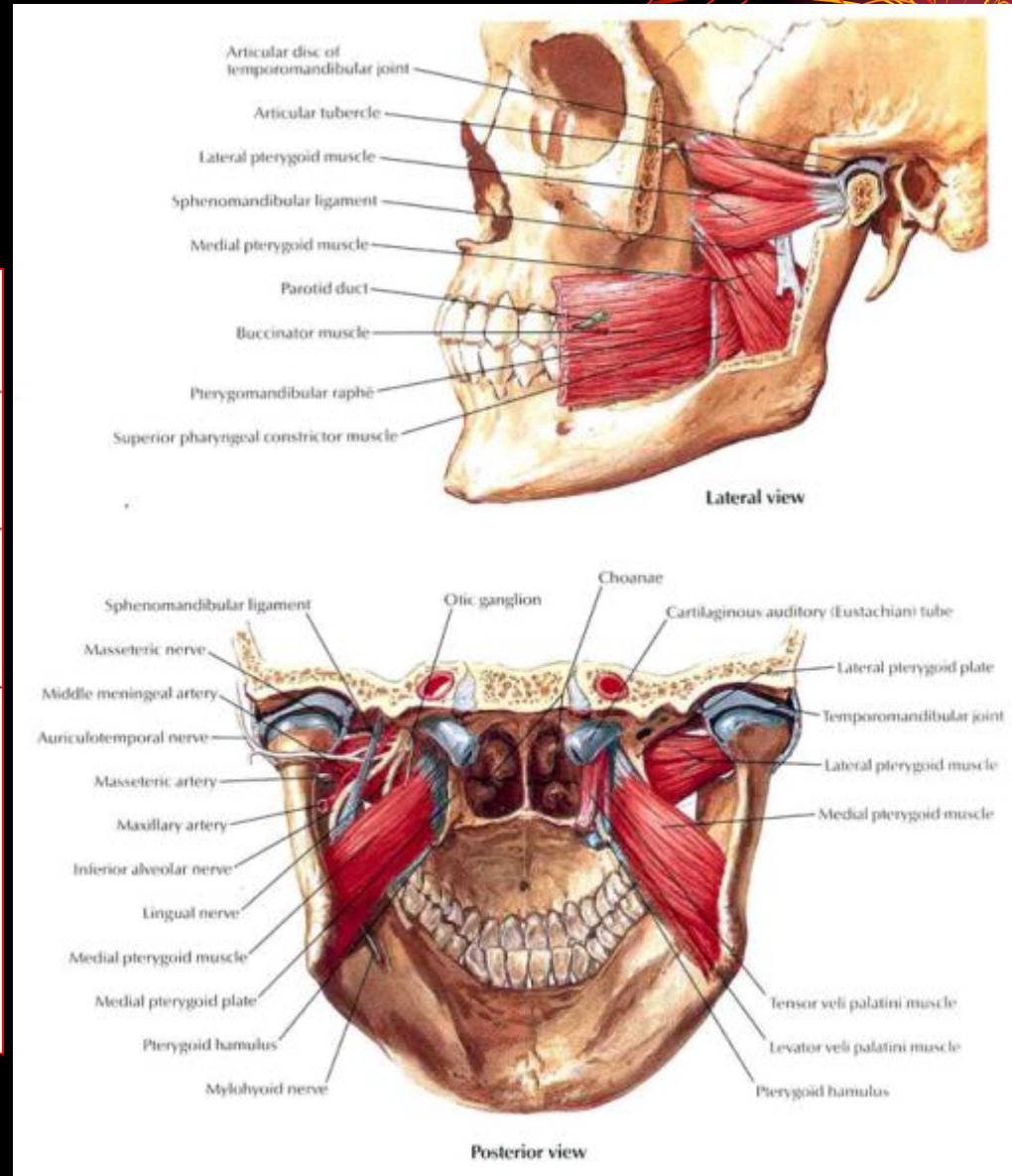




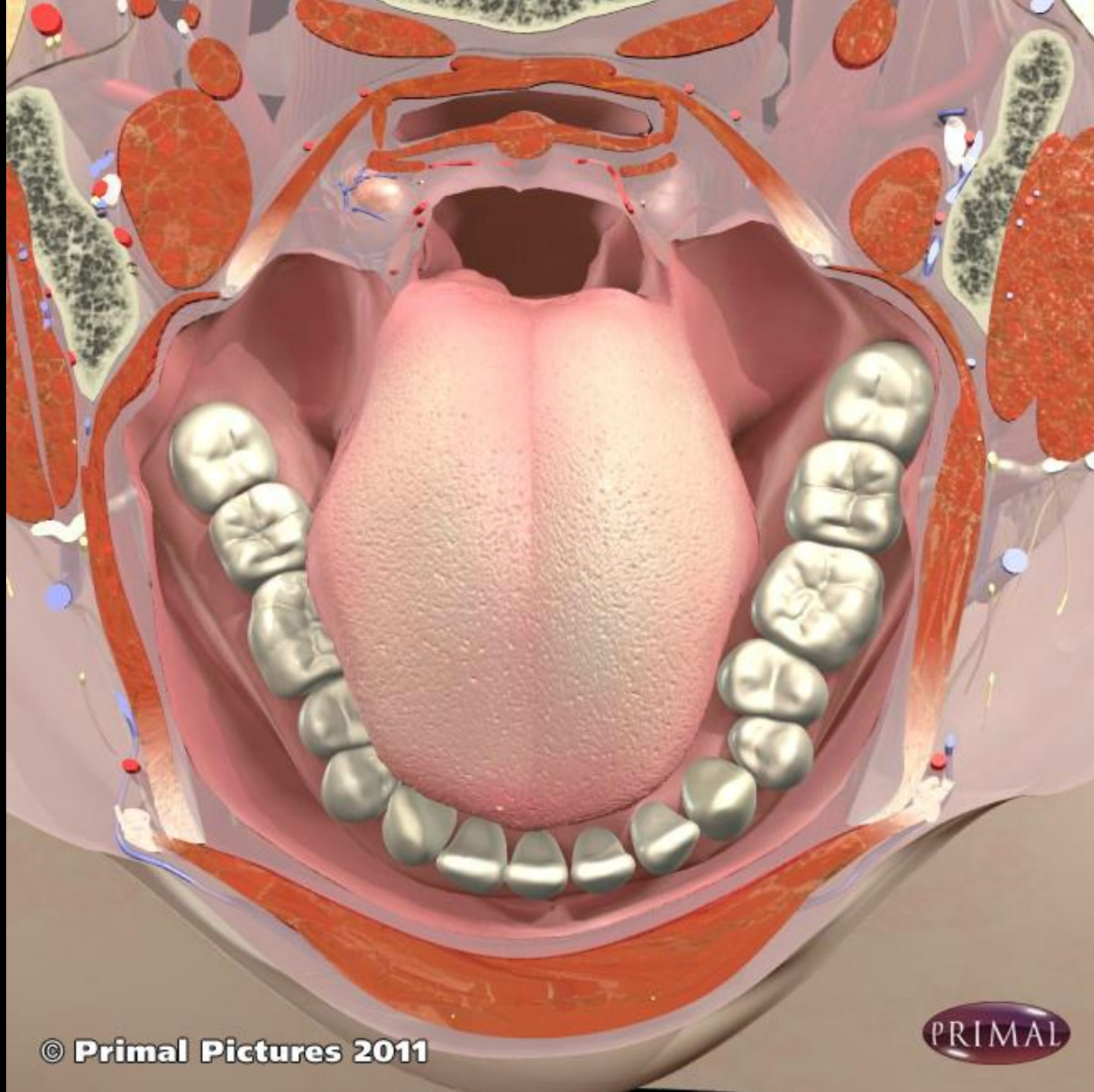
PterygoMandibular triangle




Drake: gray's anatomy for students 2nd edition

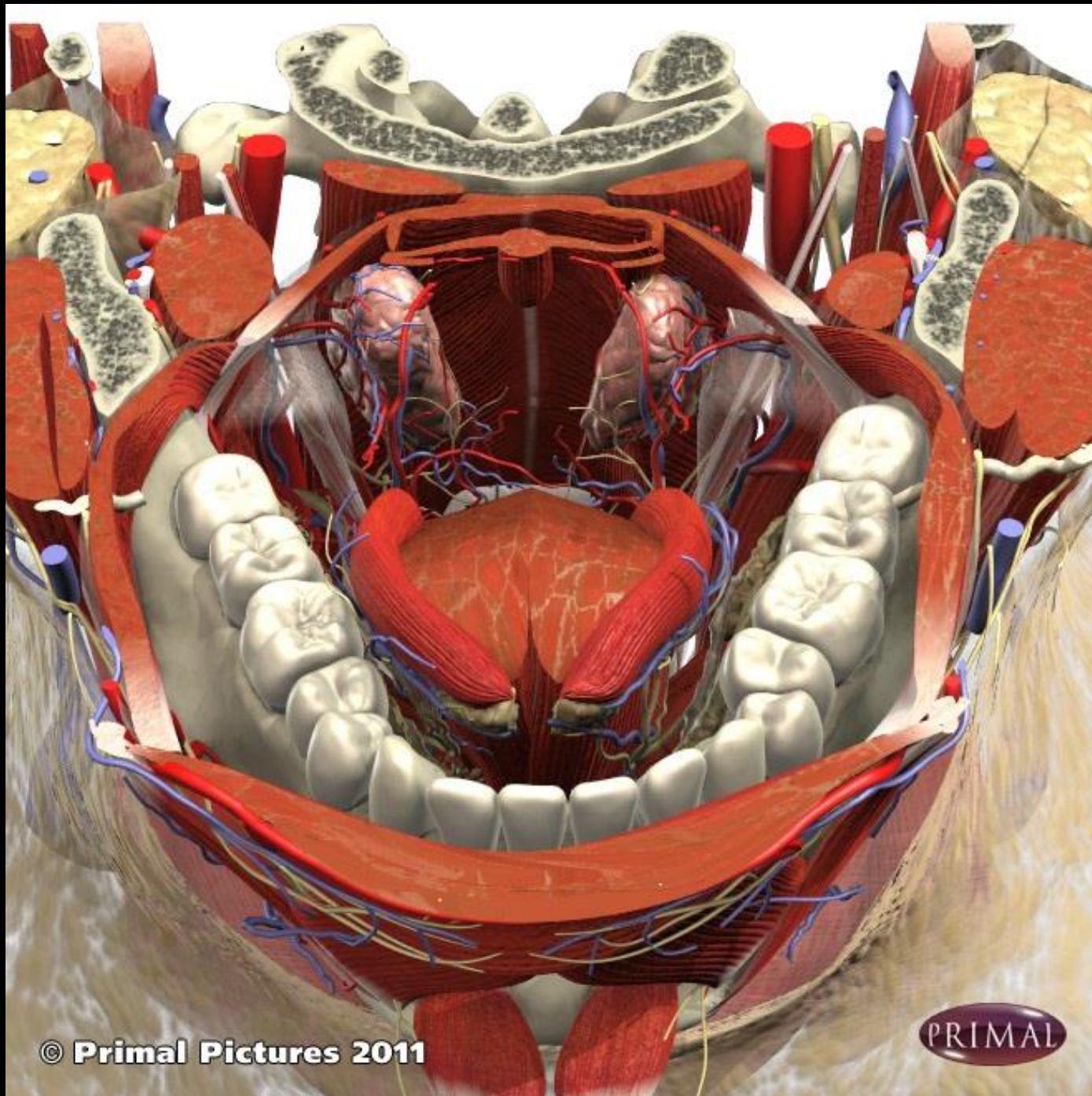


Netter's Atlas of human anatomy 5th edition





© Primal Pictures 2011

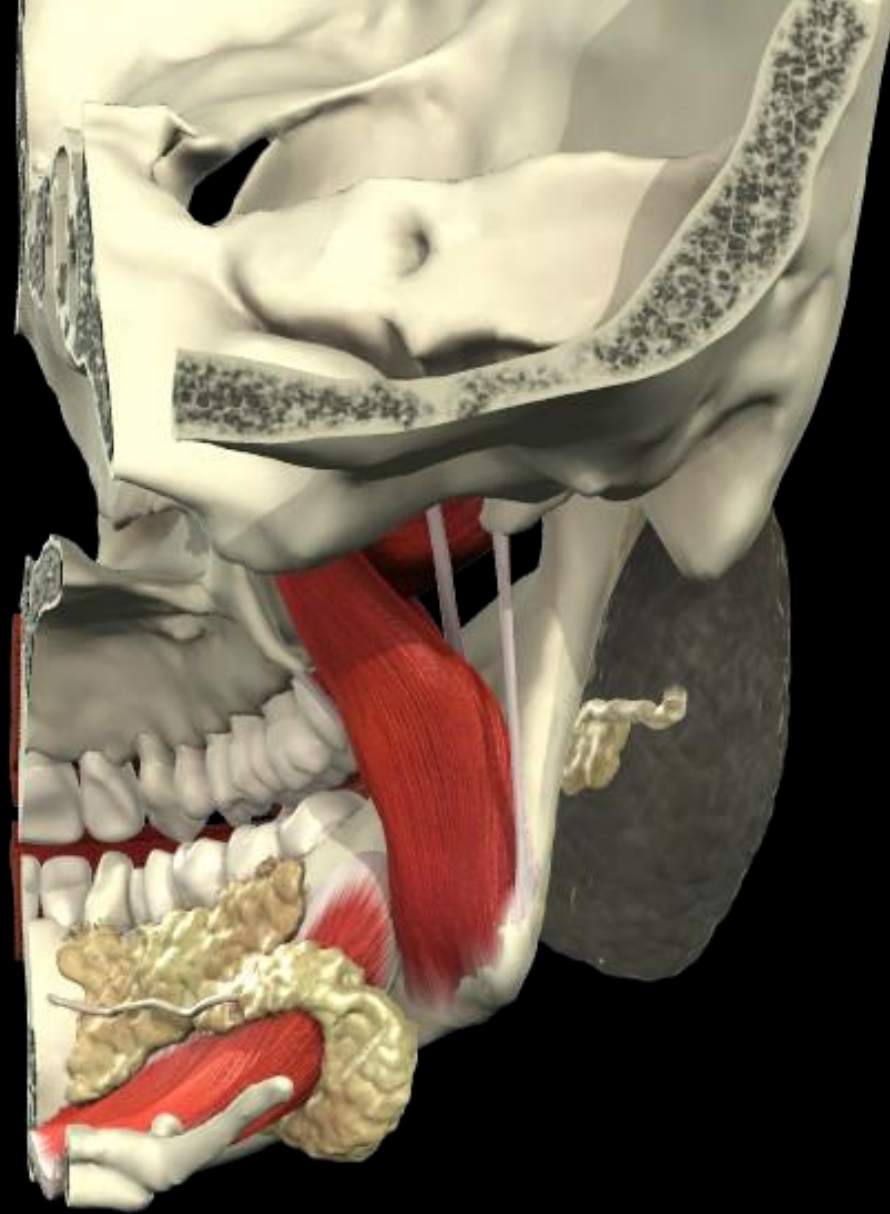






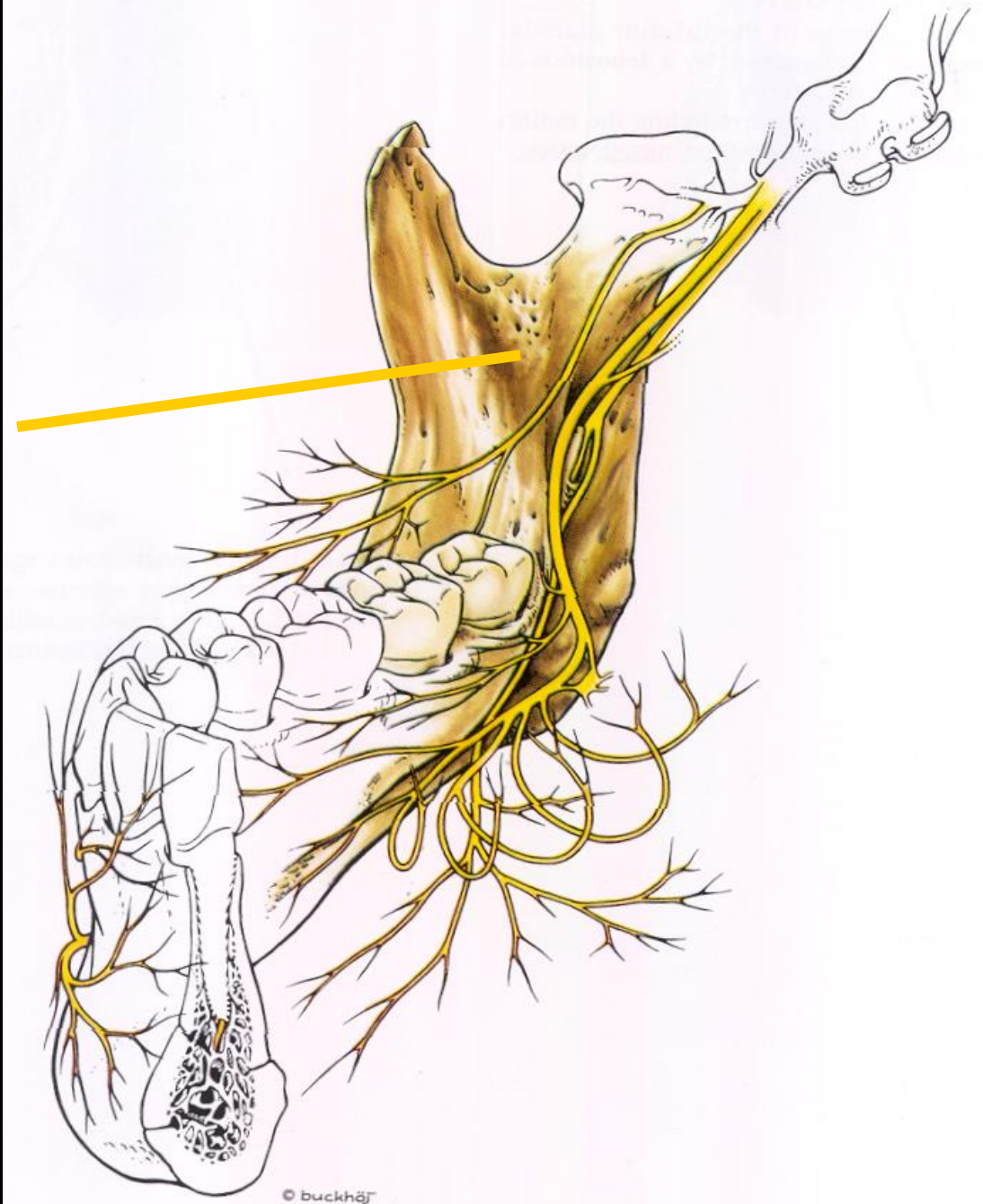
© Primal Pictures 2011

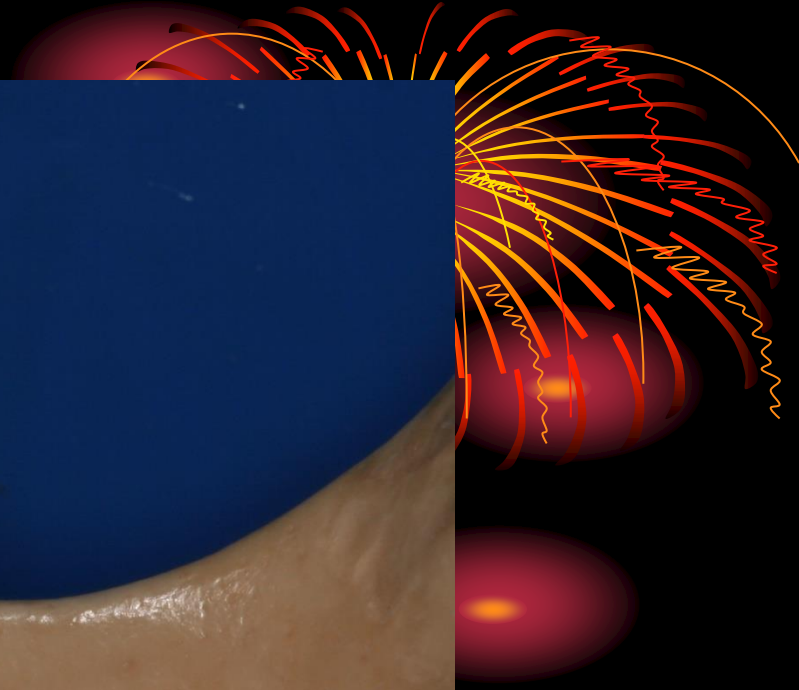
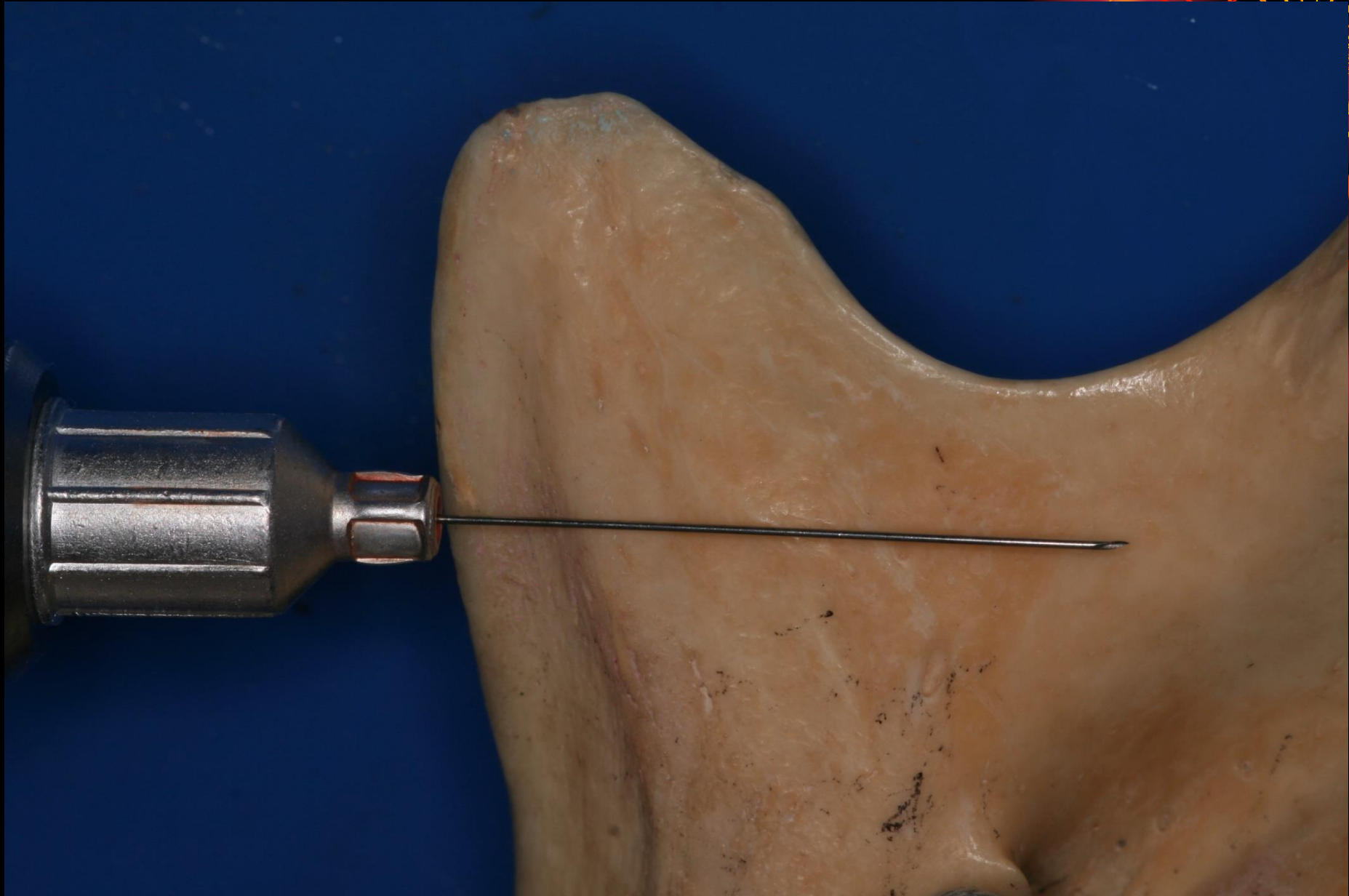
PRIMAL





The RPM injection avoids the lingula by injecting superior to it.


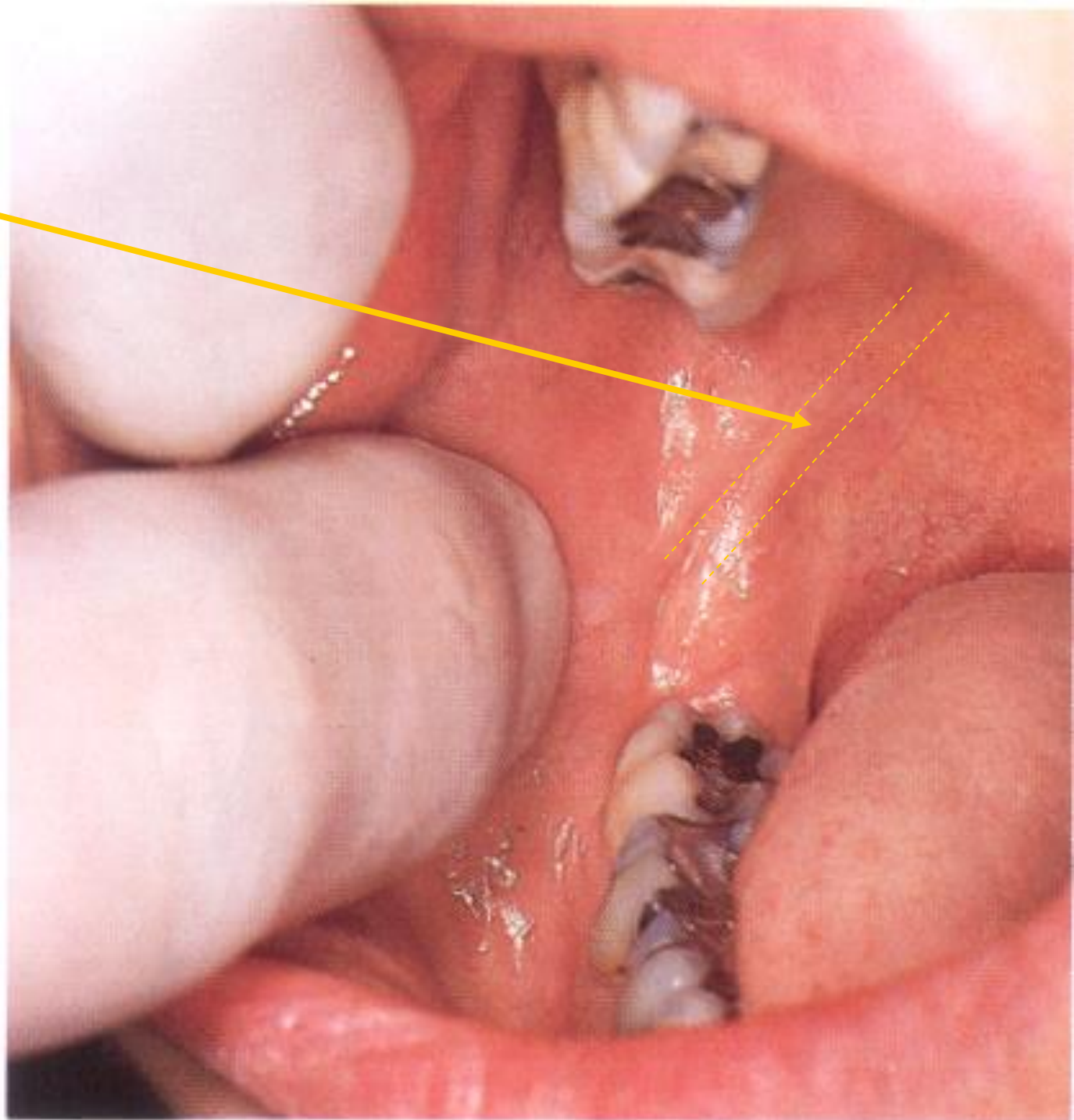





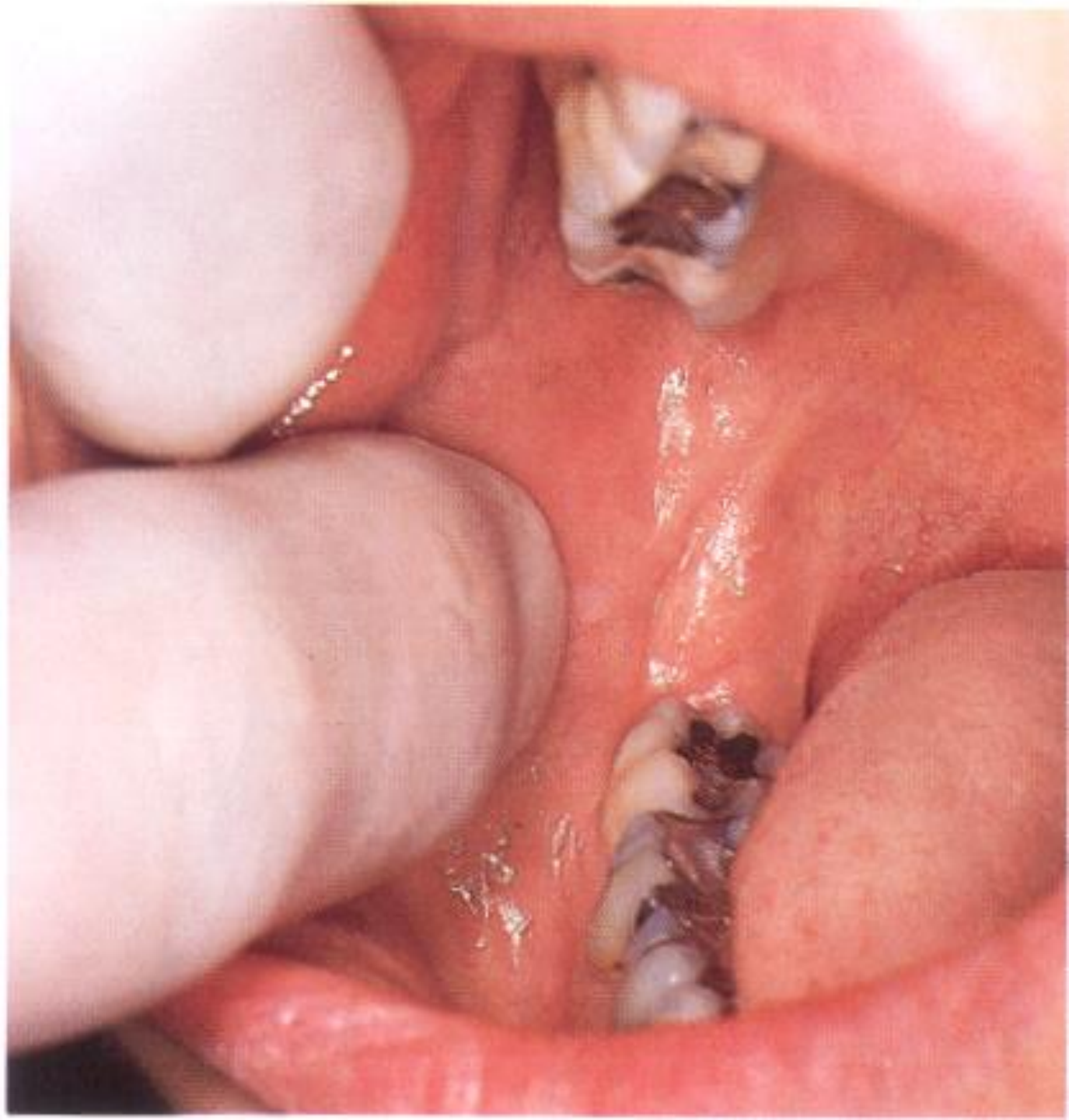
The RPM injection nicely avoids that surly medial pterygoid muscle.

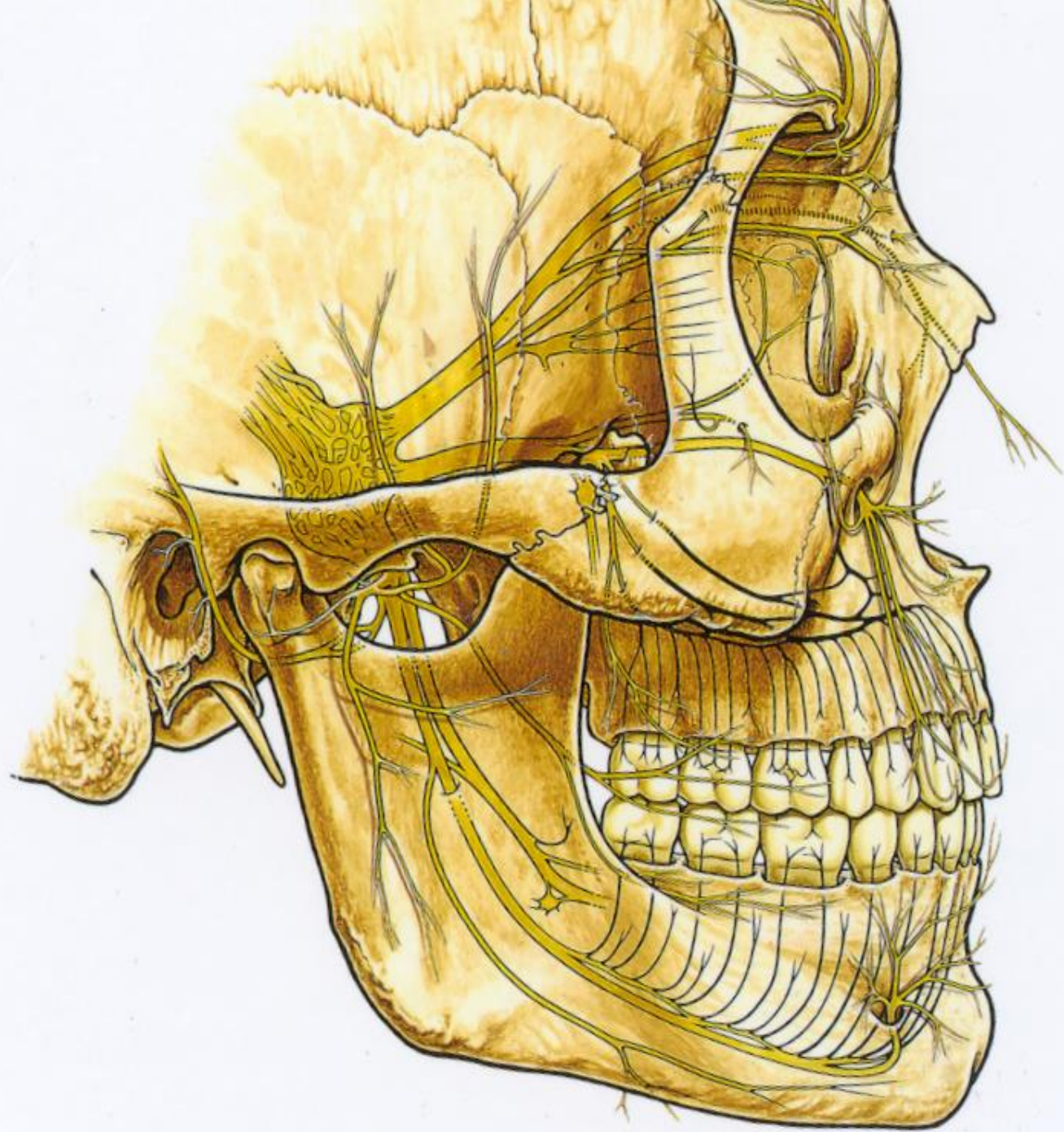
Its biggest advantage is it uses only one landmark: the bony mandible.


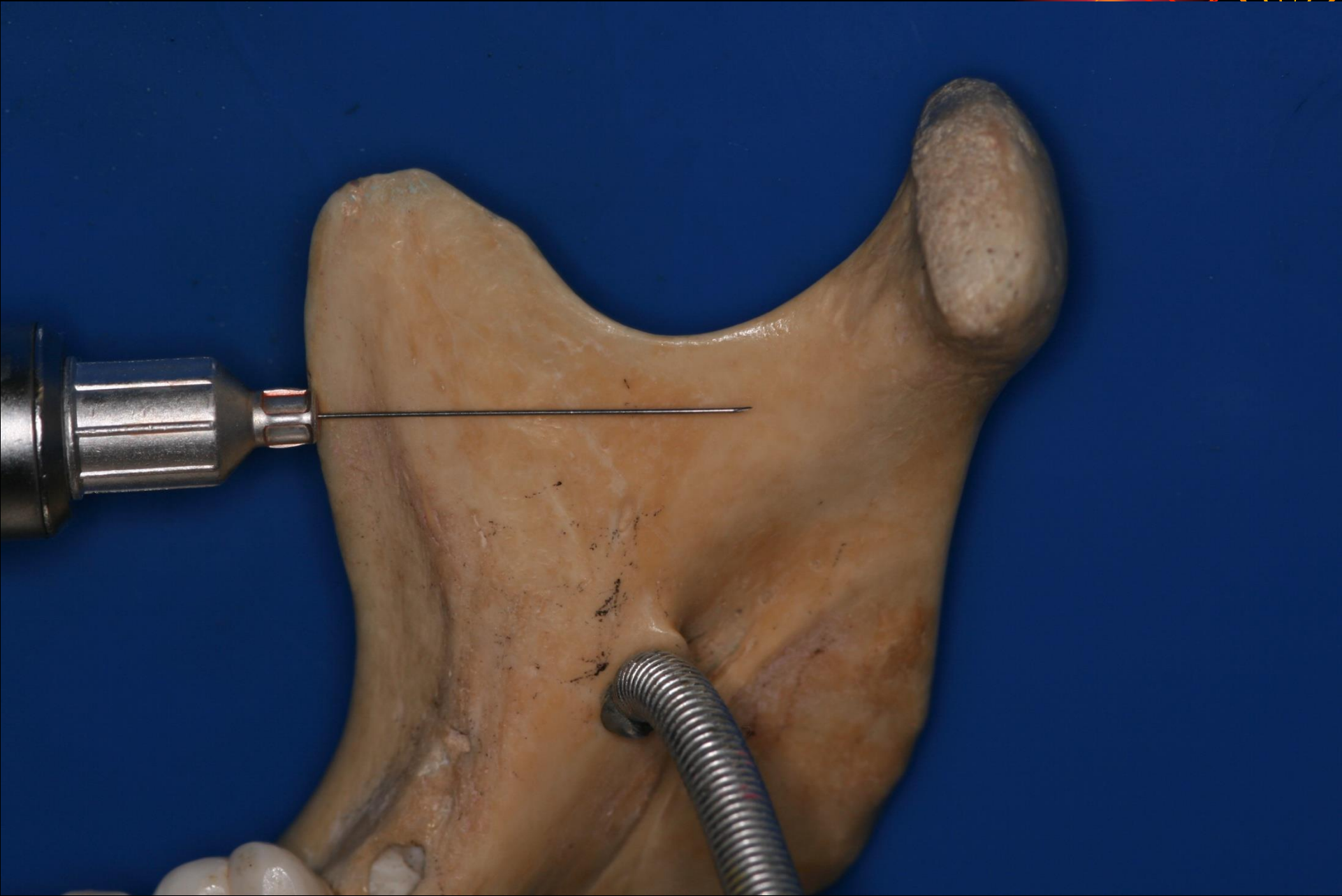
It presents only one variable, and it is not a soft tissue one, but a bony one, that can be well palpated by the operator.

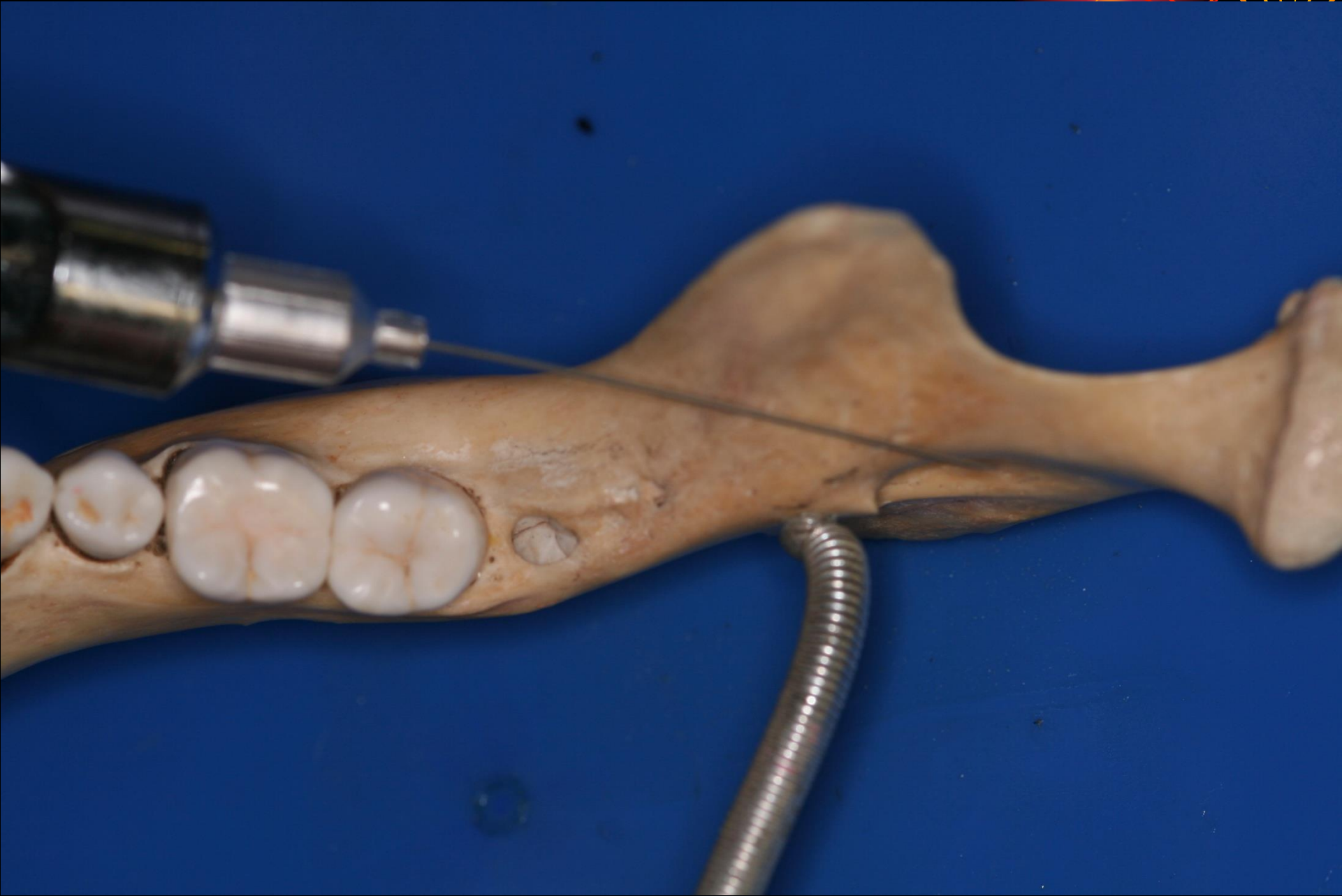


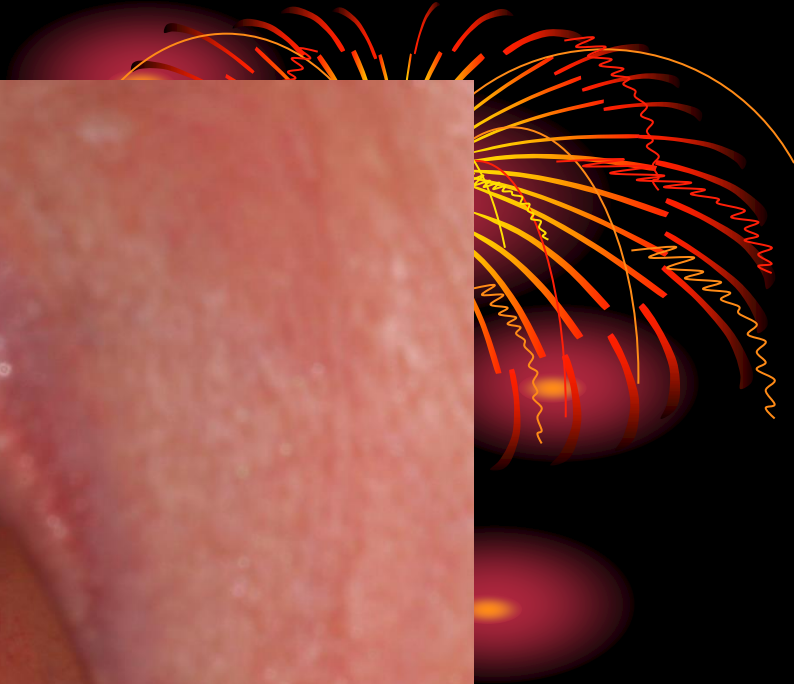
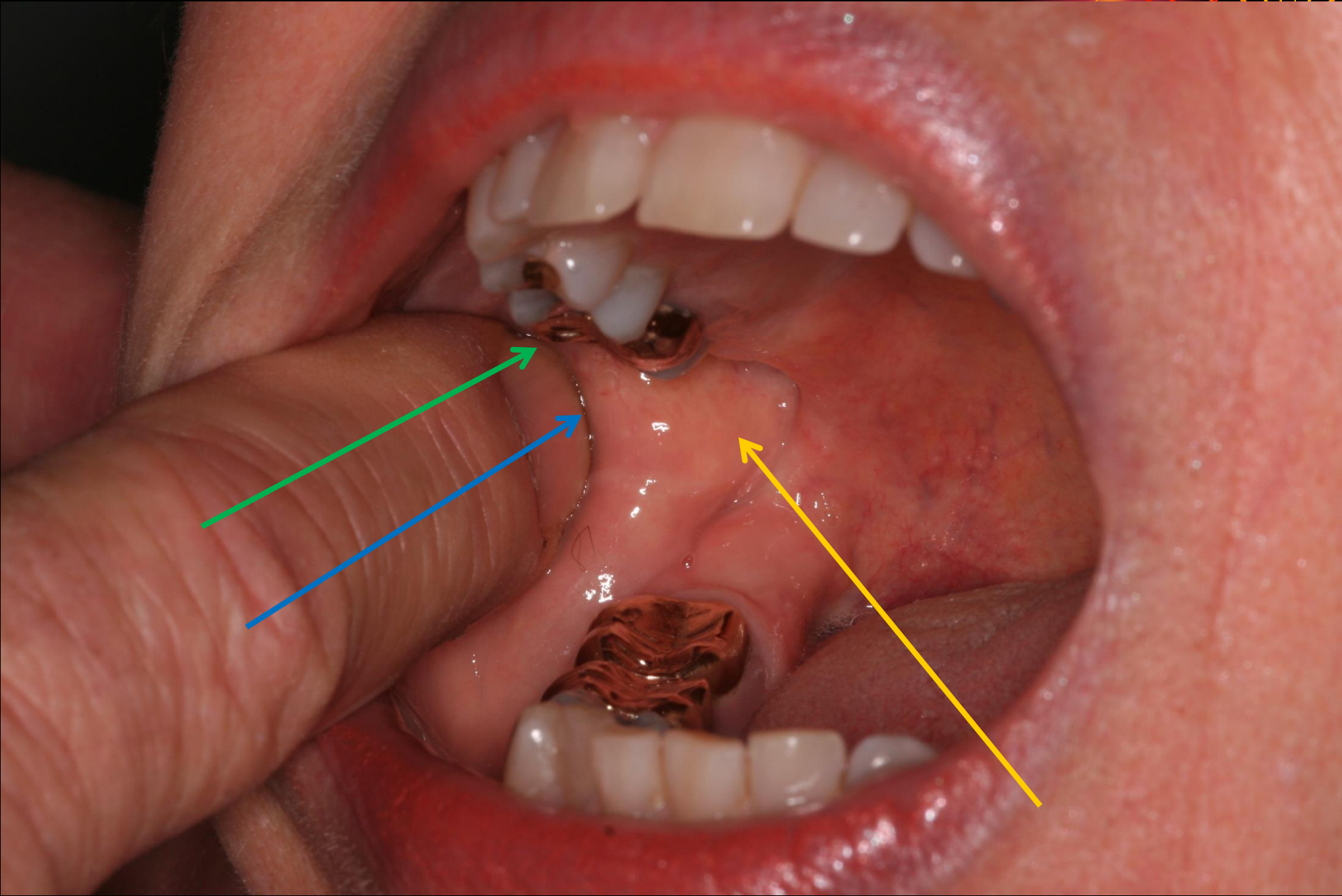
Another advantage of the RPM injection is that it will anesthetize the long buccal nerve as well as the inferior alveolar nerve, and lingual nerve with a single injection.













Inferior Alveolar Injection Technique On the Mandible



Inferior Alveolar Injection Technique



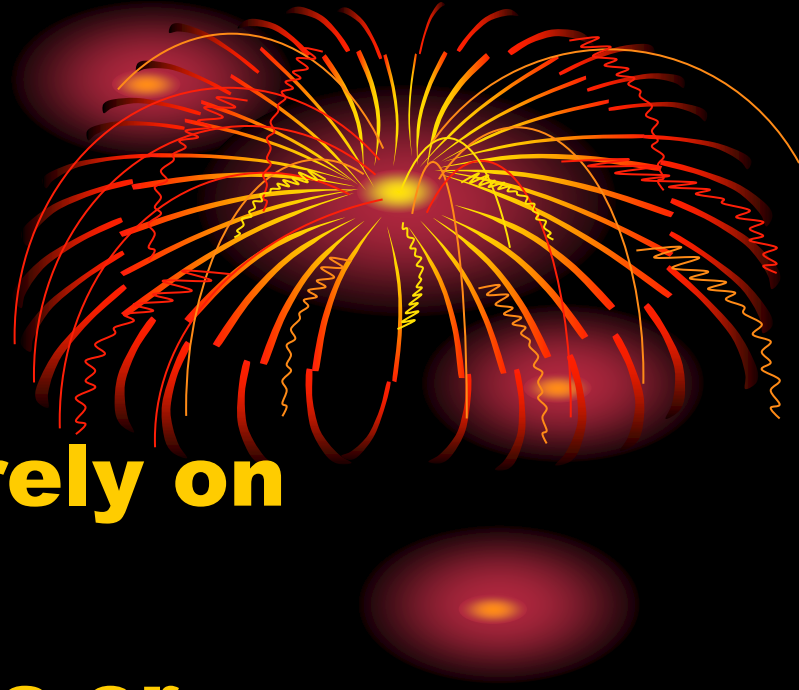Advantages of “RPM”™ injection



- **Can be preformed with a 30ga needle short (7/8” or 23MM)**
- **Idea depth to nerve is exactly to the hub of the 30ga needle (3/4 the length of a 27ga long)**
- **Can be perform with the mouth open, closed, or with a bite block in place**

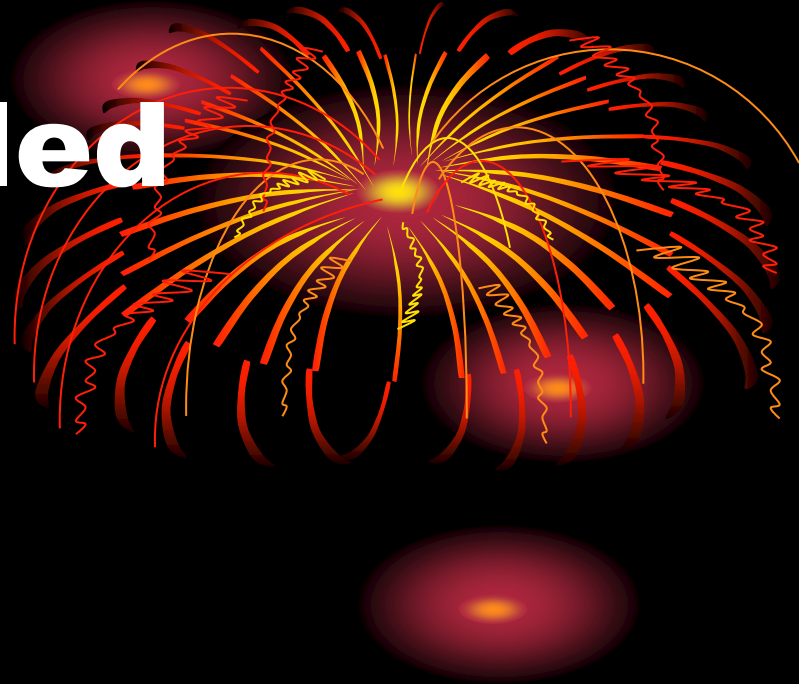Advantages


- **Injection landmarks based entirely on boney landmarks**
- **Avoids going through the muscle or ligaments to enter the pterygo-mandibular space**
- **One injection provides a full V3 division block- IAN, lingual, buccal, and myohyoid**



Common reasons for failed blocks (IAN)

- **Injection too low**
- **Injection too medial**
- **Lateral flare of the mandible**
- **Infection lower ph**
- **Accessory innervation**
- **Timing of procedure (too soon or too late)**
- **Intravascular injection**



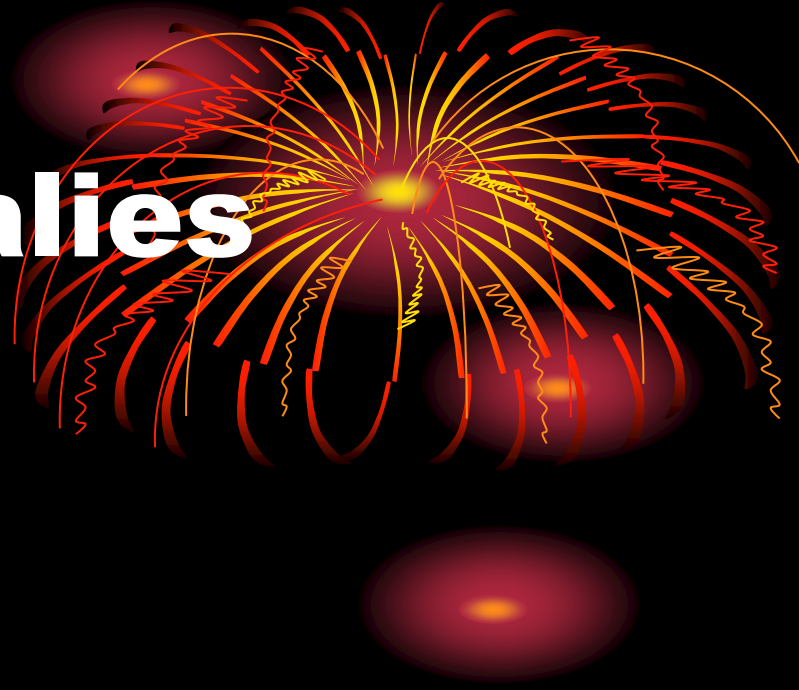

710532
EKSOL
11/08

2.5 ml
8-2

LOT

Mandibular nerve anomalies

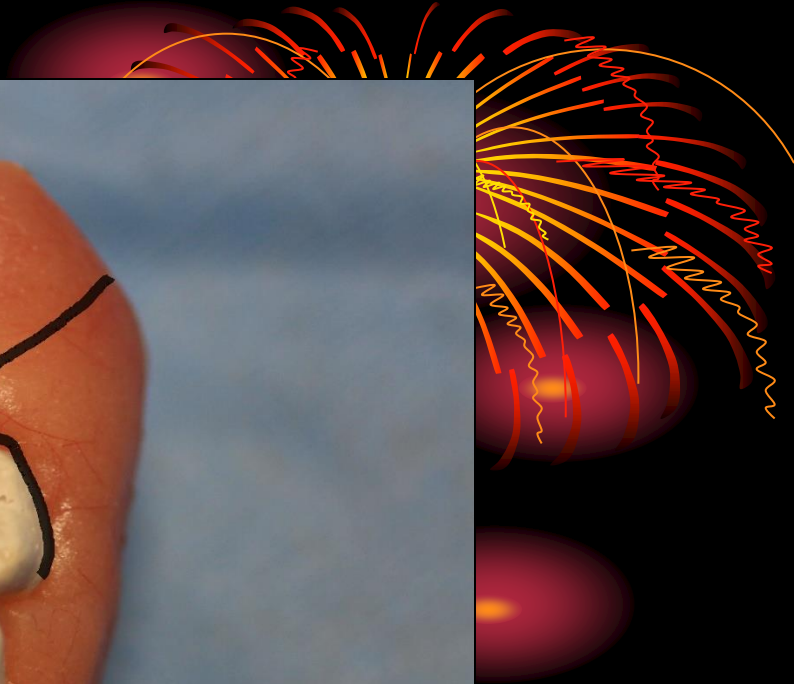
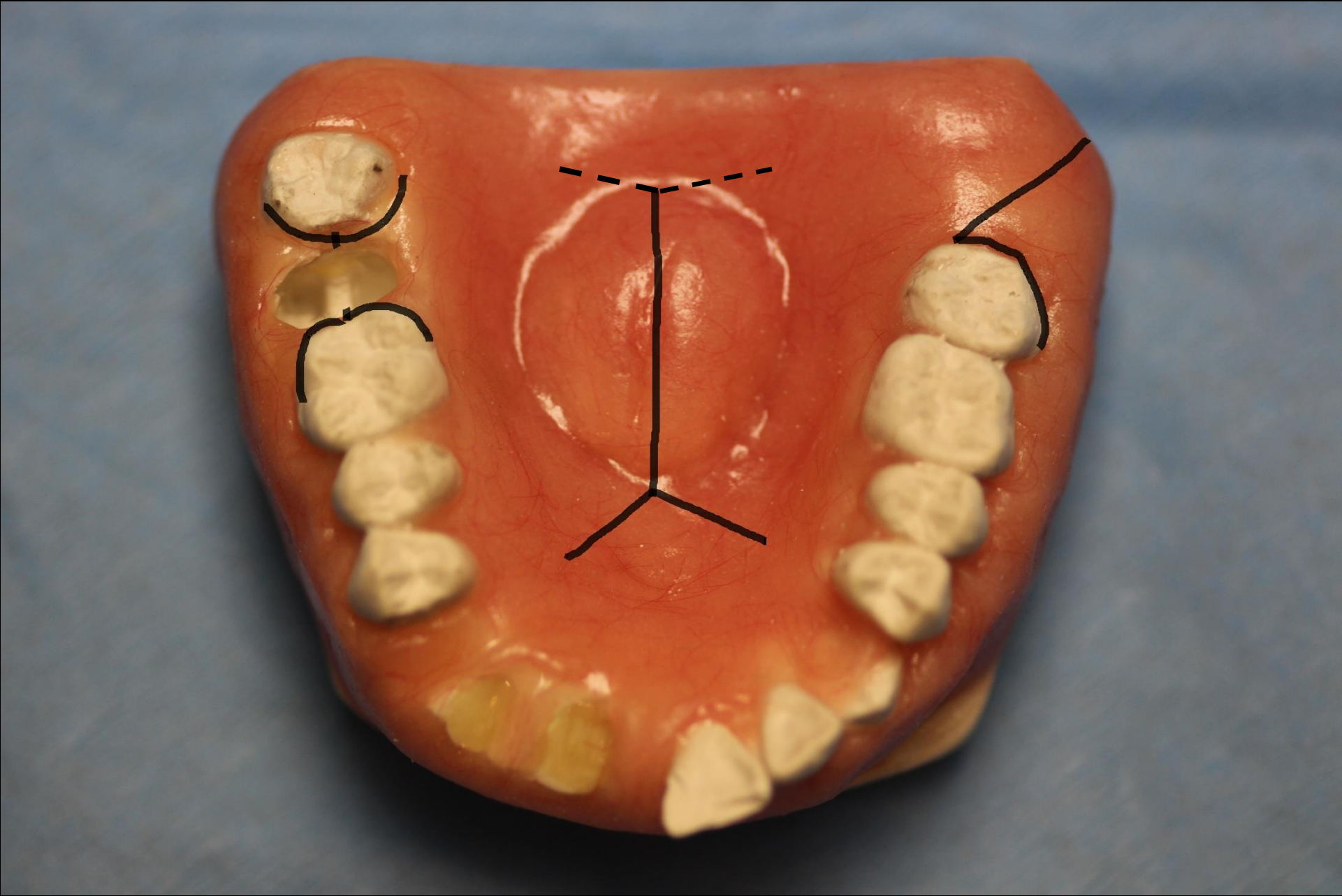


- **Accessory Mylohyoid nerve**
- **Bifid mandibular nerve**
- **Retromolar foramen**
- **Contra-lateral innervation of anterior teeth**

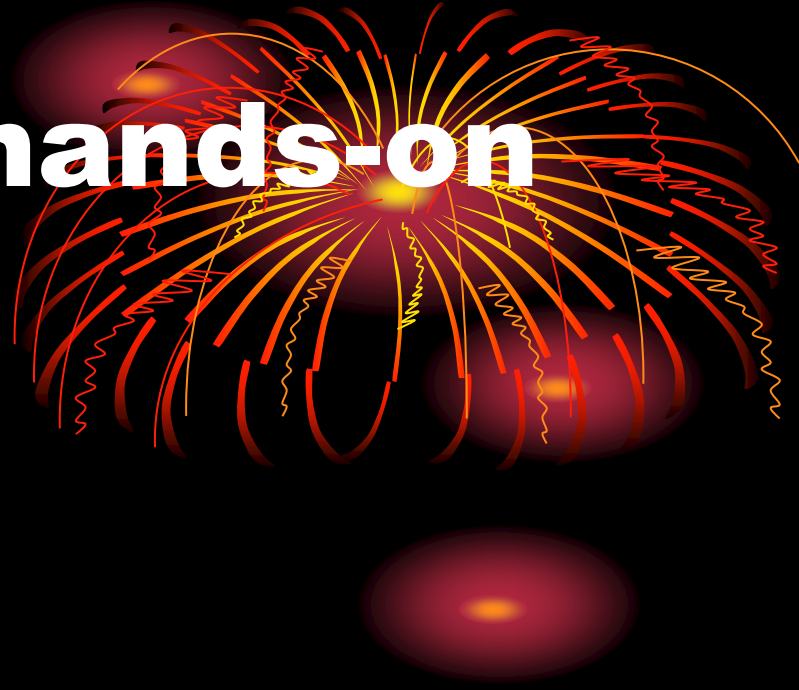

Surgical examples:

- **Socket preservation with and without membrane**
- **Microtome/luxator removal of root tips**
- **Surgical removal of impacted 3rd Molars**
 - **Soft Tissue**
 - **Partial Boney**
 - **Horizontal Complete boney**
- **Removal of Palatal and Mandibular Tori**
- **Orthodontic canine exposure with/without bracket**



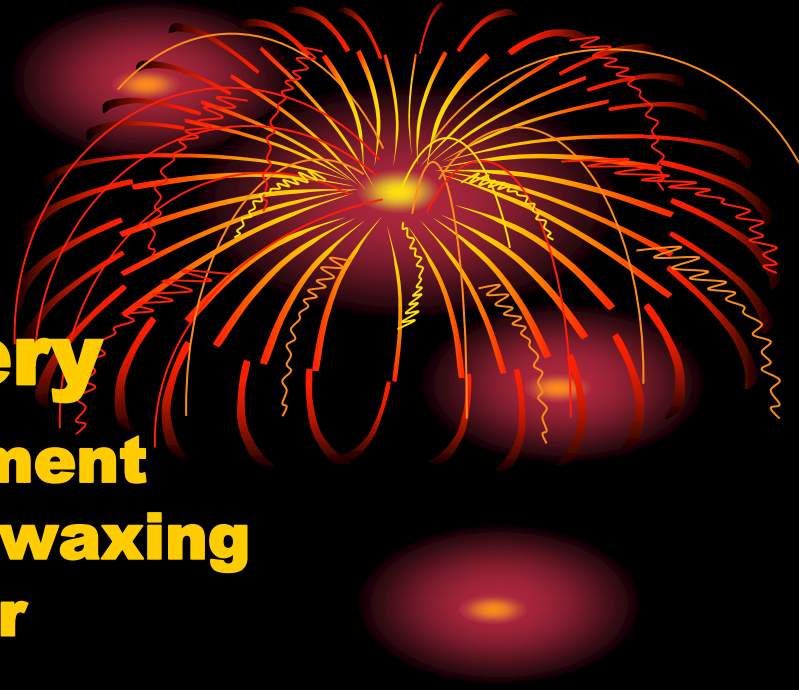Socket Preservation a hands-on approach



- **Review of Extraction techniques**
- **Socket defects**
- **Barrier Membranes**
 - **Resorbable and Non-Resorbable**
- **Bone Grafting Materials**
 - **Advantages and Disadvantages**
 - **Synthetics, Allogenic, Autogenous, and Xenografts**

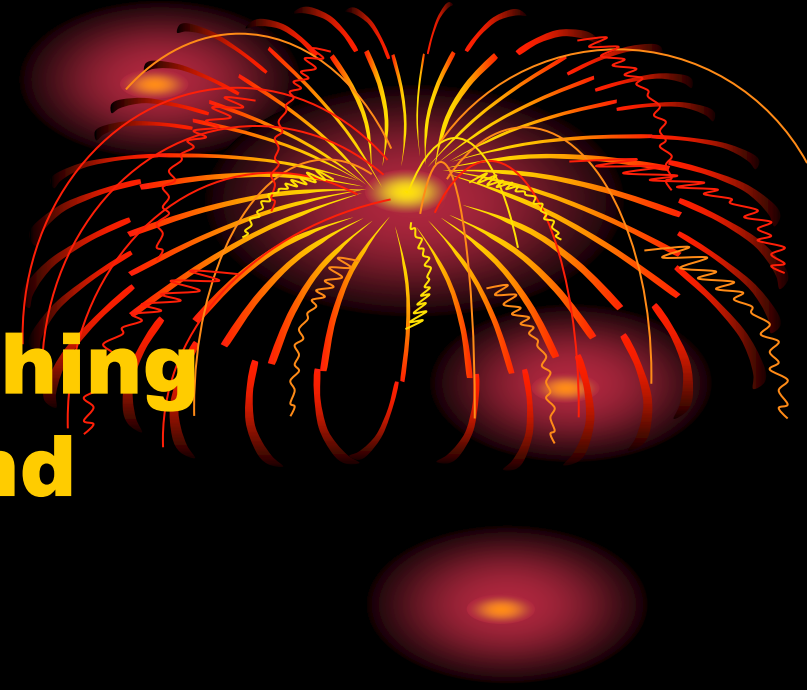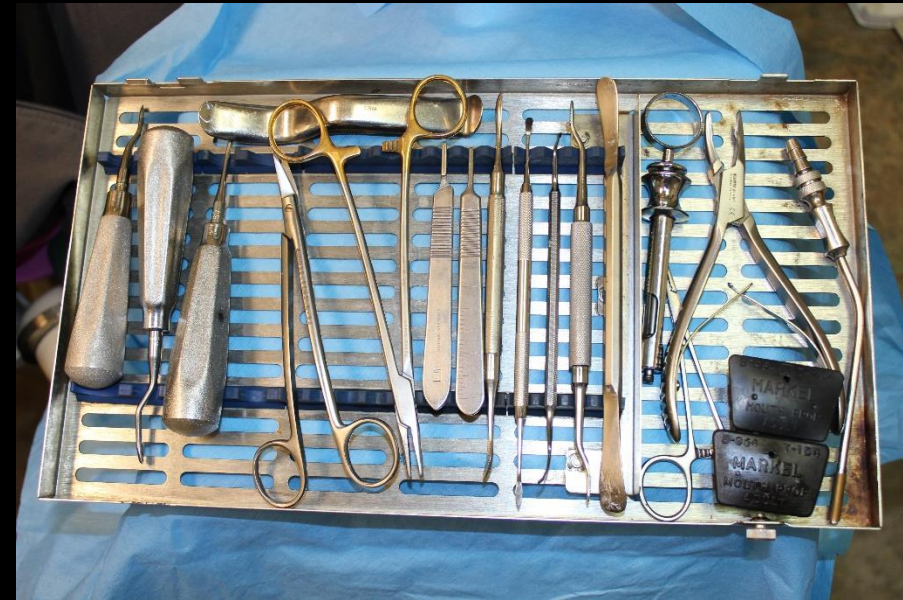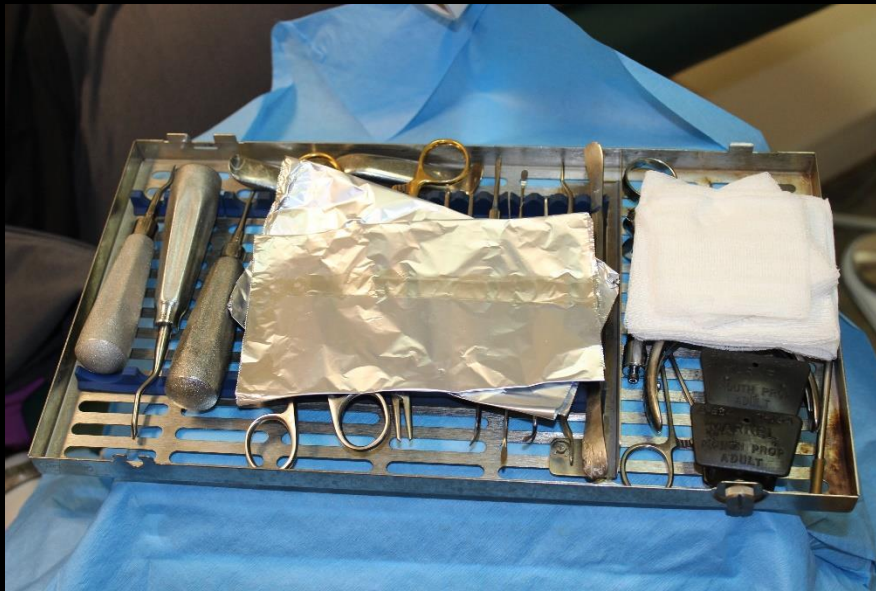Extraction techniques:

- **Flapless Atraumatic Surgery**
 - **Usually the smaller the instrument the better, such as a Woodsen waxing instrument, Bandit elevators, or Microtome's**
 - **Sectioning with a fine bur and lots of irrigation (avoid any bone removal)**
 - **Easy X-Trac system**
 - **The Ögram System**
 - **The “Tip it” “an Innovative root tip extractor”**
 - **Specialized “atraumatic forceps” (Misch forceps)**



Instrument sets

- **Cassette cases-have everything but forceps, microtomes, and select elevators in set up**
- **Contains sterile gauze and sterile foil for light handles**



Instrument list

Elevators
E92
E46R
E301 #369-6804

Bone File
BF21 #368-2903

Periosteal
P9 #372-1529

Woodson
PH2

Curette
CL85 #368-5807

Bard Parker
SZ.3 #128-6038

Minnesota
#CRM 0810

Hemostat
#086-3472

Ronguers
#373-1544

Scissors
Dean #089-3800

Needle Holder
NH5038 #371-5810

Seldin retractor
(P23) #369-0013

Ash Forceps
FX13 #086-4058

Upper Anterior forceps
150AS #370-8955

Lower Anterior Forceps
151S #086-4934

Upper Right Molar Forceps
89 #370-6579

Upper Left Molar Forceps
90 #370-6587

Upper 3rd. Molar Forceps
210 #086-4371

Cow Horn Forceps
23 #370-6488

East/West Elevators
25 #086-2169, 26 #086-2177

Root Tip Picks
2 #086-2540, 3 #086-2557

Millers Elevators
(E71) #369-5319, (E72) #369-5327

Chisels
2mm #497-0232
4mm #497-0240
6mm #497-0257

Mallet
#371-2254

Cotton Pliers
(DP18L) #368-4602

Explorer
(EXD3CH) #368-0196

Scissors
4 1/2" #499-5403

Ligature Pliers (GAC Ortho)
#GAC503

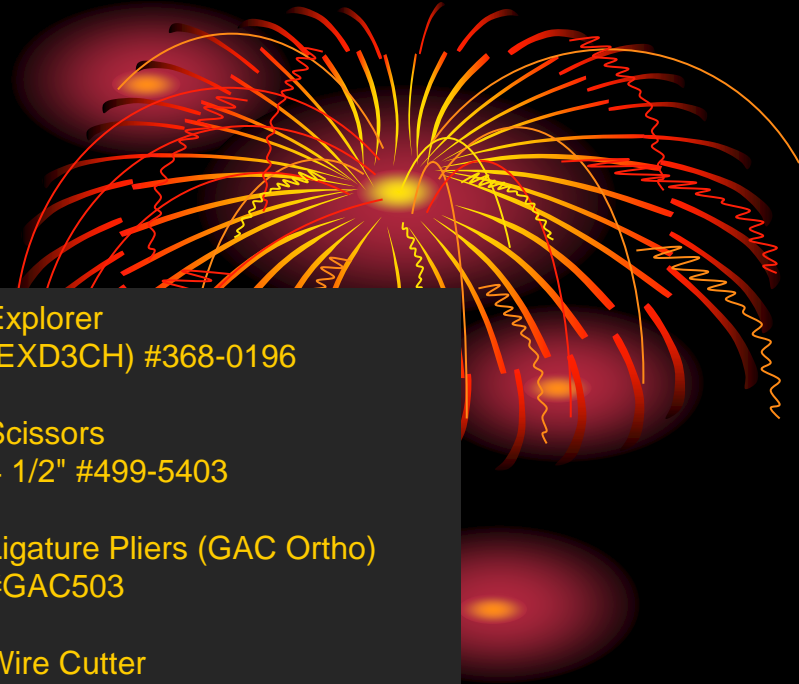Wire Cutter
#OGD-1000

Surgical Cassettes
#IMOSO (oral surgery)

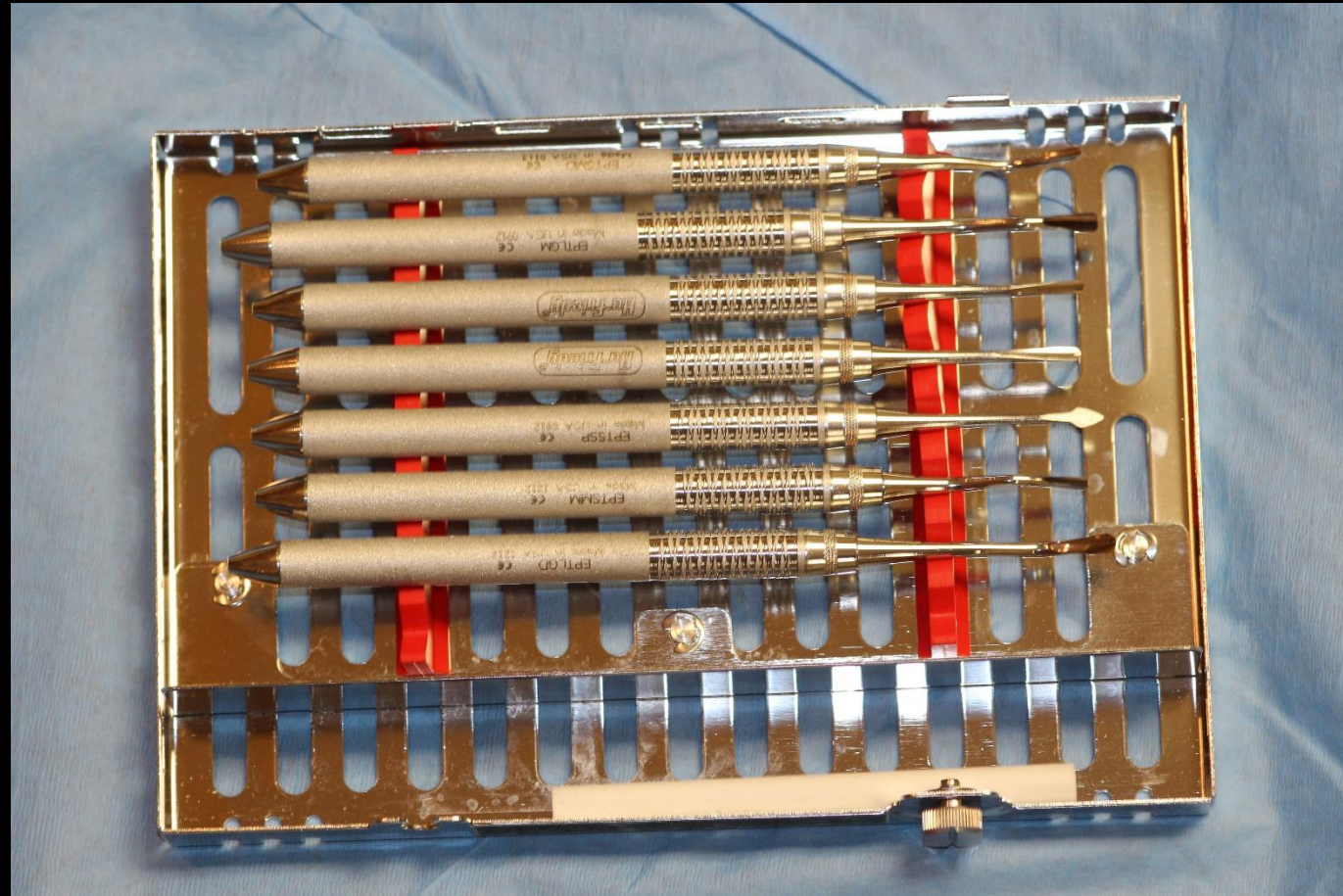

Twisted Bandit Elevators
(Walter Lorenz)
#09-0356

Upper Incisor Pedo Forceps
(150s) #370-6314

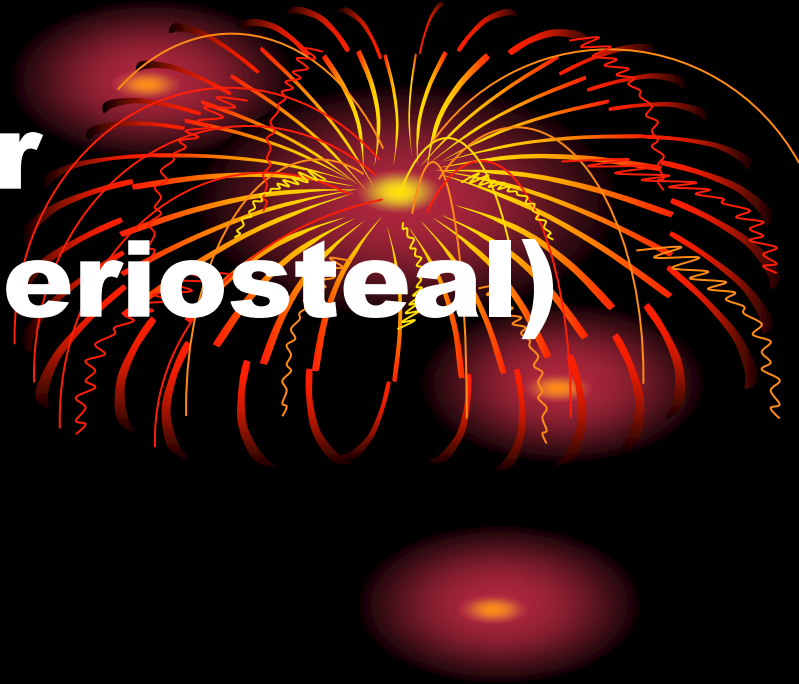
Lower Incisor Pedo Forceps
(151s) #370-6322



Microtomes-luxating hybrids (a cross between periostomes and elevators)



Woodson elevator (PH2 Hourigan modified periosteal)





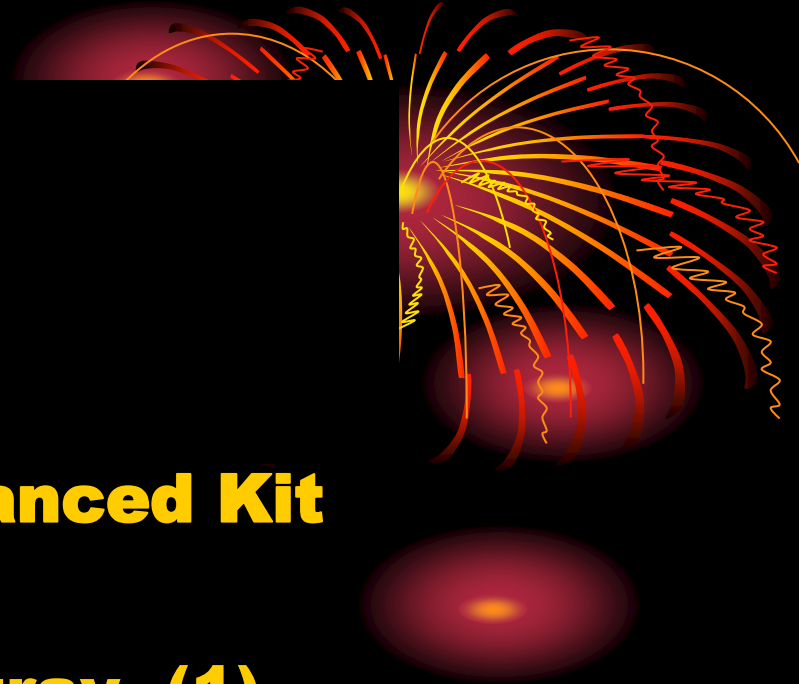
Evolution doesn't imitate...it innovates!

- **K8000 Easy X - TRAC System Advanced Kit**


Advanced Kit.

Includes: (1) Custom sterilization tray, (1) Easy X-Tractor, (1) set of 3 drills, (2) 28mm extraction screws, (2) 30mm extraction screws, (2) 33mm extraction screws, (2) 35mm extraction screws, (1) re-engineered Ratchet, (1) Protector Plate-left, (1) Protector Plate-right, (1) new Premium burr block, and a Tutorial CD-ROM.

\$1,749.99



Loss of a Tooth Results in a Ridge Defect 90% of the Time




Types of Defects

- **TYPE I – 32%** Bucco-lingual with no vertical loss of height
- **TYPE II – 3%** Apico-coronal with no bucco-lingual loss
- **TYPE III – 55%** Combination of both directions of bone loss

Literature Review

Conclusion: Significant knowledge exists of the healing process of extraction wounds, including contour changes caused by bone resorption and the cascade of histological events in both animals and humans. **The resorption of the alveolar process following tooth extraction in both jaws is significantly greater on the buccal aspect. The reduction in width of the maxillary alveolar ridge is greater than the loss of height. The mandible has up to 4 times greater resorption than the maxilla** The significant loss of tissue contour takes place during the first month after extraction, **averaging 3 to 5 mm at 6 months. Schropp et al reported a reduction of 50% of the width of the alveolar ridge at 12 months. Bays reports 40-60% loss of height and width after 1 year.**



What else can we expect to happen to the soft tissue surrounding the extraction site?



1. Predominately buccal ridge resorption – lingual repositioning
2. The vertical height of the ridge will be less than the proximal crest of the adjacent tooth
3. Loss of adjacent Papilla to 3 mm coronal to crest of bone of the adjacent tooth
4. Free gingival margin apical migration of 2 mm or greater depending on the crestal bone position at the ovate pontic site

External Ridge

- Collapse papilla
- Collapse FGM


- Minimal ridge collapse

- Re-epithelialized
- Start to remodel ridge

- 2/3 of remodeling
- Greater buccal loss
- Greater horizontal than vertical
- Lost papilla and FGM

- 50% horizontal loss 12mm to 6mm avg.
- Greater in mandible

Complete remodeling



Extract

1 week

1 month

6-8 weeks

3 months

1 year

2 yrs

- Coagulum
- Provisional CT matrix

- Woven bone
- Loss of bundle bone

- Cortical ridge
- Woven and lamellar bone

Lamellar bone and marrow

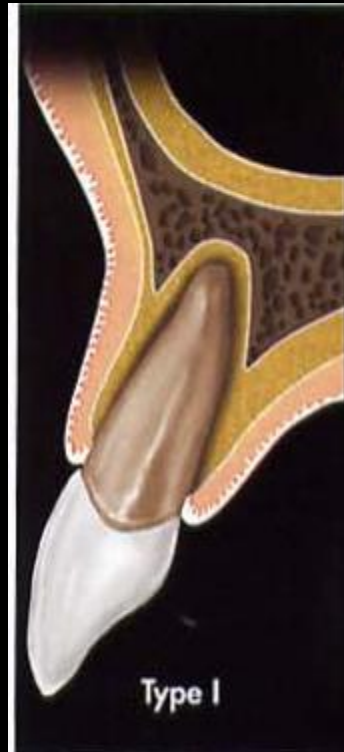Histologic

Post extraction change in alveolus and gingiva

References: Schropp 2003; Lekovic 1997; Araujo, Lindhe 2003; Amler 1969; Barone 2008

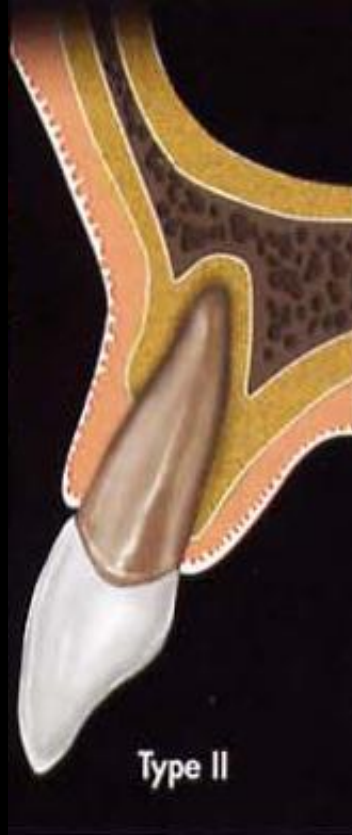Socket Defects

- **Classifications:**
 - **Type I – The facial soft tissue and buccal plate of bone are at normal levels in relation to the cemento-enamel junction of the pre-extracted tooth and remain intact post extraction**



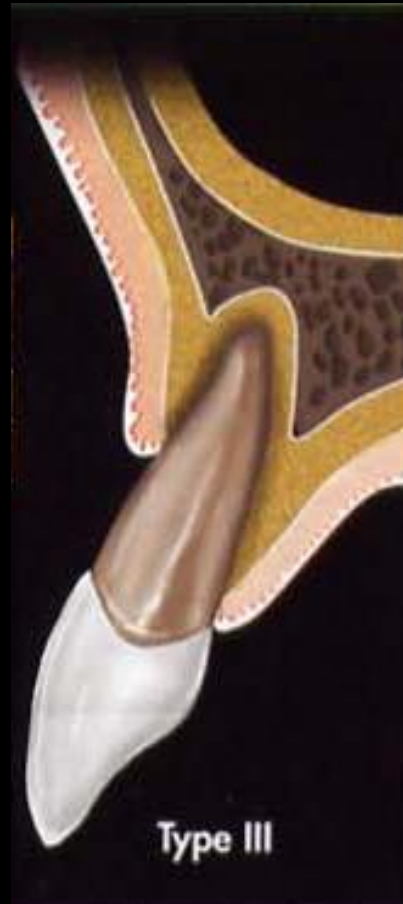Socket Defects

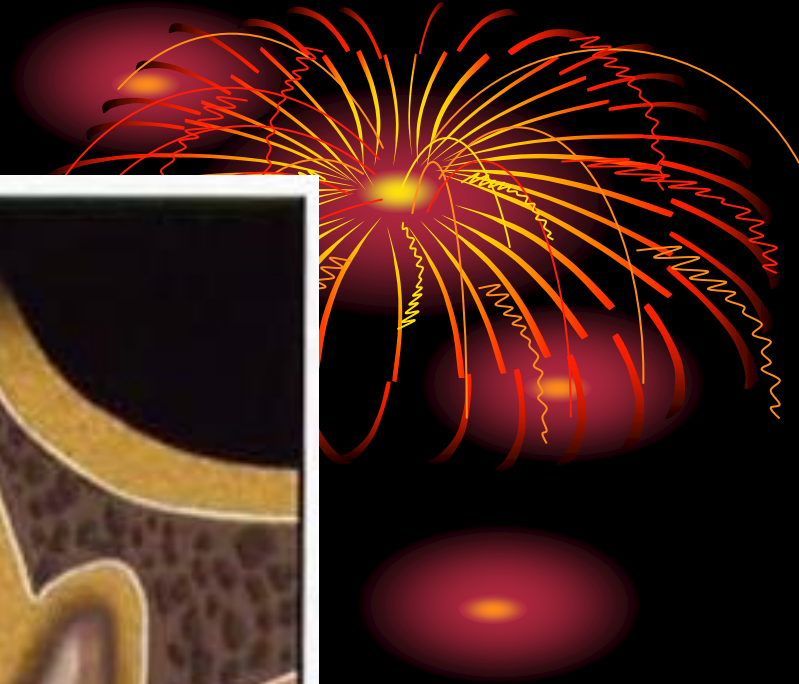
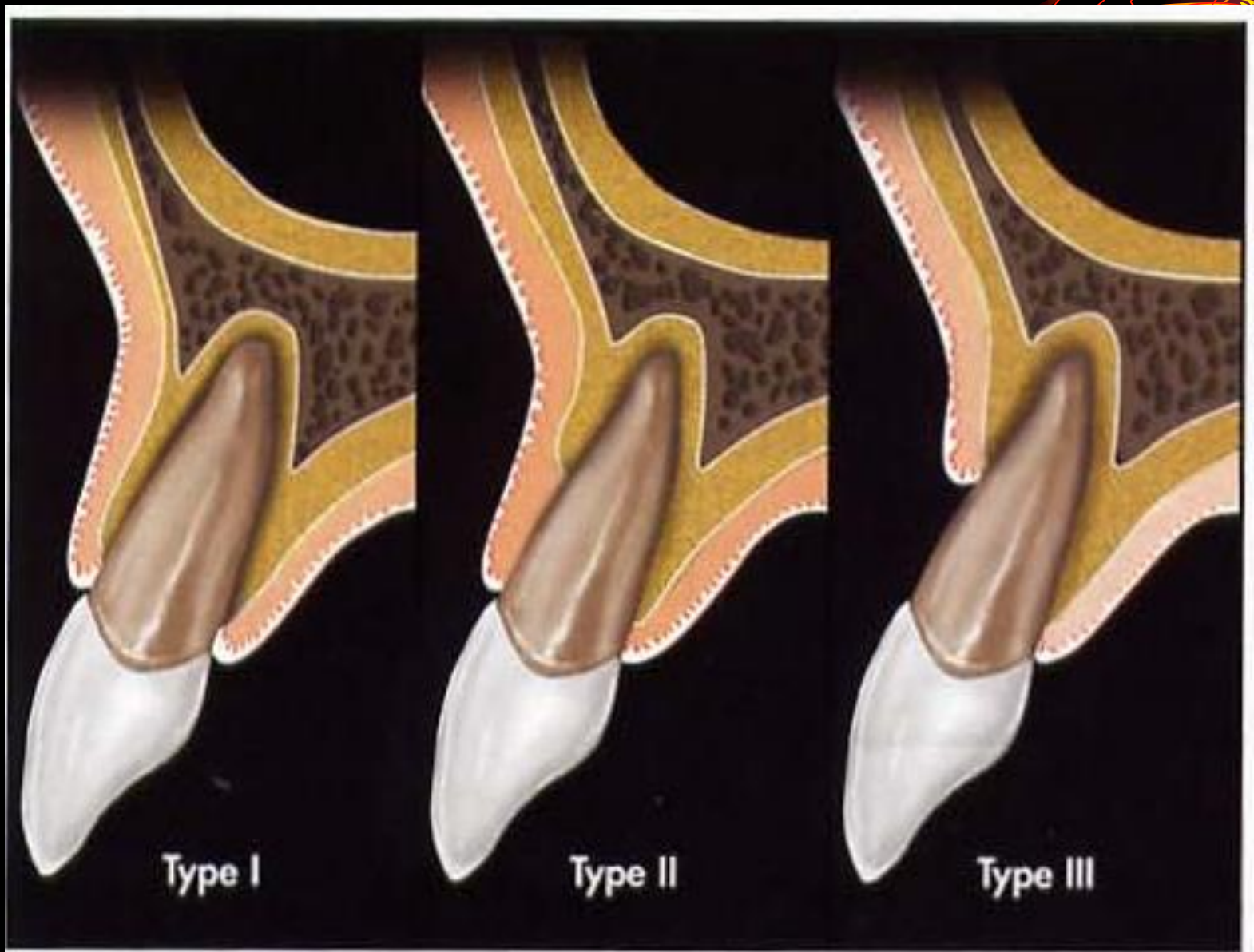
- **Type II- Facial soft tissue is present but the buccal plate is partially missing following extraction of the tooth, can also be a fistula or buccal periodontal defect present. Most common with vertical root fractures of endodontically treated teeth.**



Socket Defects

- **Type III- The facial soft tissue and the buccal plate of bone are both markedly reduced before and after tooth extraction.**





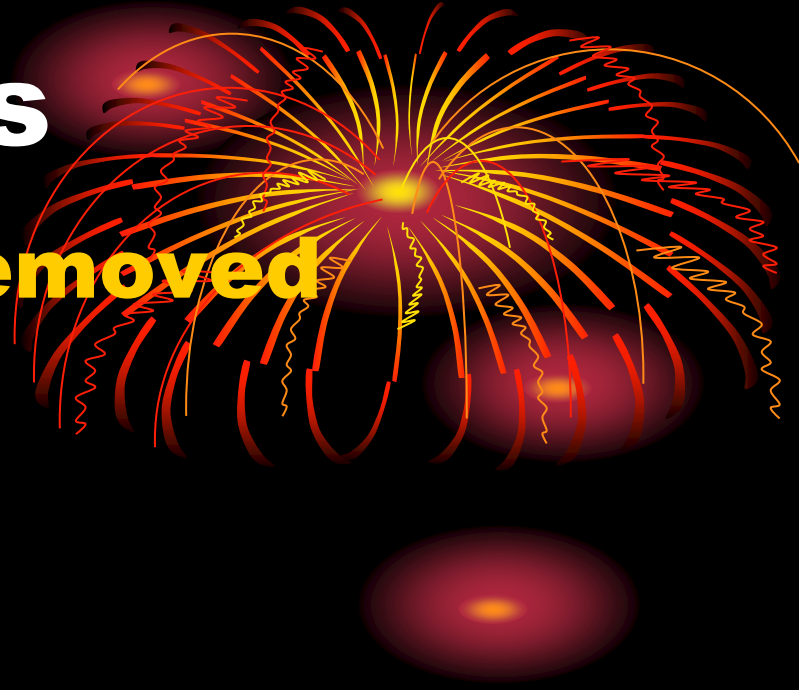
Barrier Membranes




- **Resorbable**
 - **Very Short 7-14 days**
 - **Short 4-6 weeks**
 - **Moderate 8-12 weeks**
 - **Long 4-9 months**
- **Materials**
 - **Human/Allograft -dermis (Alloderm), cardiac pericardium, and Autogenous tissue**
 - **Animal/xenograft- Bovine, Porcine, and shellfish**
 - **Synthetic**

Barrier Membranes

- **Non-Resorbable (must be removed at some point)**
 - **e-PTFE (Teflon- Expanded Polytetrafluoroethylene)**
 - **Plain/Smooth (Gortex)**
 - **Dense Micro-textured (d-PTFE cytoplast TXT-200)**
 - **Titanium Reinforced e-PTFE**
 - **Titanium Mesh**
 - **Gold, Platinum, Titanium Foils**
 - **Silicone (Supramid)**
 - **Porous Polyethylene (Medpor)**



Additional Enhancing Materials




- **PRP – Plasma Rich Platelets**
- **PRF – Plasma Rich Fibrin**
- **GEM -21 Growth factor enhanced matrix rhPDGF-BB**
- **Infuse – recombinant Bone Morphogenic Protein**
- **PostPlant -(K2H enhanced) Vitamin**

Bone grafting Materials

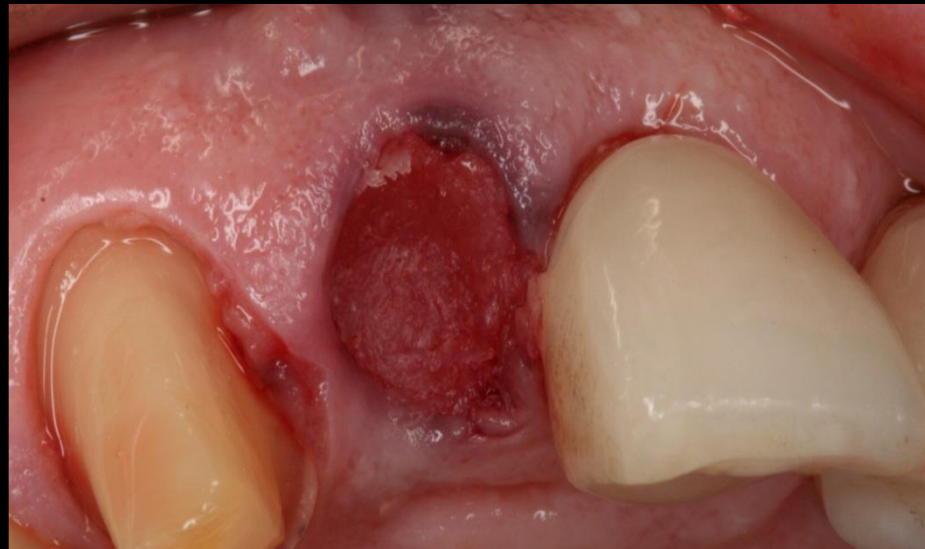



- **Autogenous- SELF “The Gold Standard”**
 - **Membranous- Cranium, Maxilla, and Mandible**
 - **Endochondral- Iliac crest, Tibia, and Fibula**
- **Xenograft- different species, Animal grafts**
- **Allograft/Homograft- same species graft**
- **Syngeneic- genetically identical (maternal twins)**
- **Synthetic- Man Made or altered**
 - **Ceramics -Hydroxappetite-non Resorbable and Resorbable types, beta-Tricalcium, porous Alumina**
 - **Bioactive glass- Perioglass and Biogran**

The “Bio-Col” Technique Ridge Preservation




Bio-Oss bone graft –plus—CollaPlug =Bio-Col

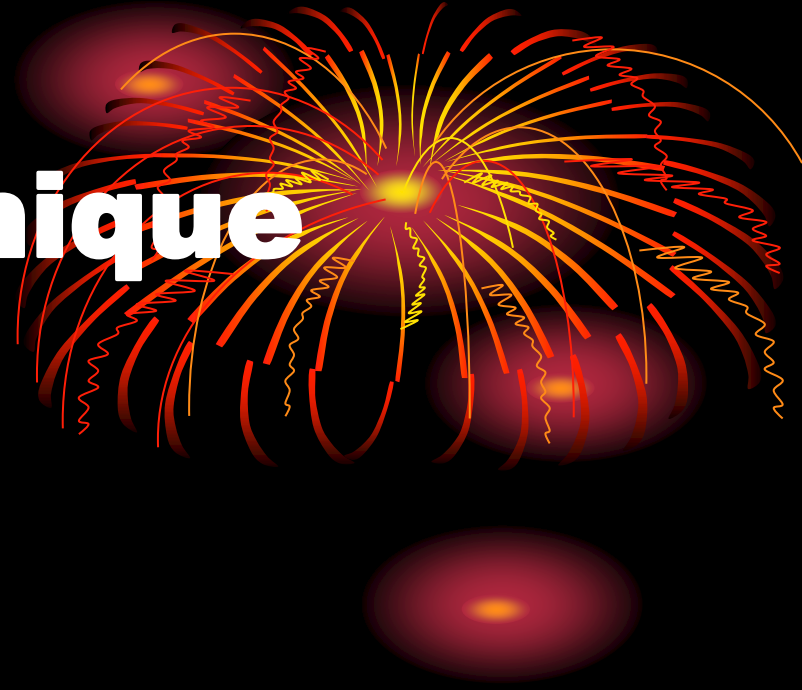


The “Bio-Col” Technique



- **Clinical goals**
 - **Preserve existing Hard and Soft Tissue**
 - **Minimize or Eliminate Post Extraction Bone Resorption**
 - **Prevent Soft Tissue Collapse**
- 

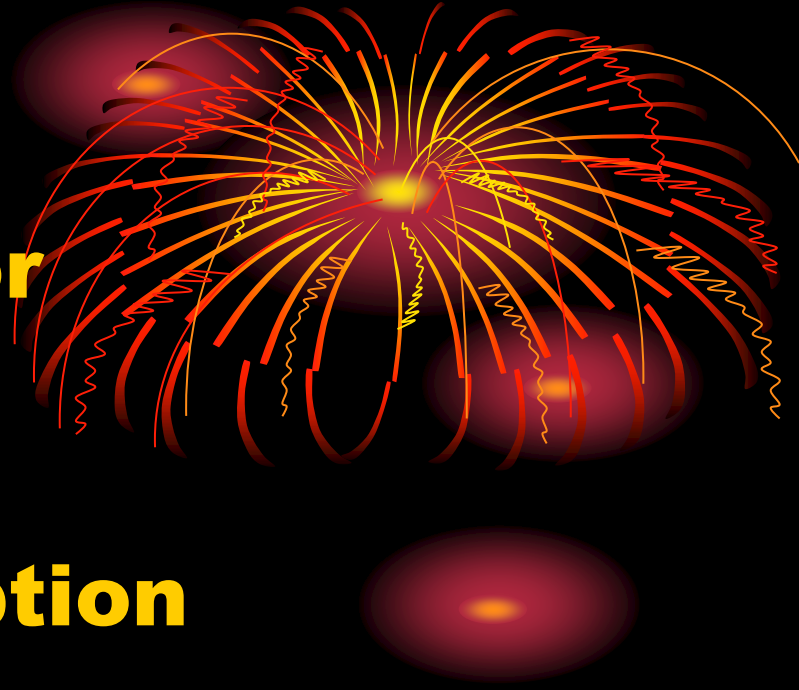The “Bio-Col” Technique



- **Biologic goals**
 - **Maximize invasion of Osteoprogenitor Cells**
 - **Provide a slowly Resorbing Osteoconductive Scaffold**
 - **Isolate Surgical site from Oral Environment**


Bone grafting Biotechnology
Conditions for successful Osteoconduction

- **Scaffold must be bio-inert or Bioactive**
- **Material should be slowly replaced by bone via resorption and substitution during remodeling phase of bone**
- **Micro-topography similar to bone**
- **Material should favor tissue in growth and bony deposition**
- **Porous and Hydrophilic**



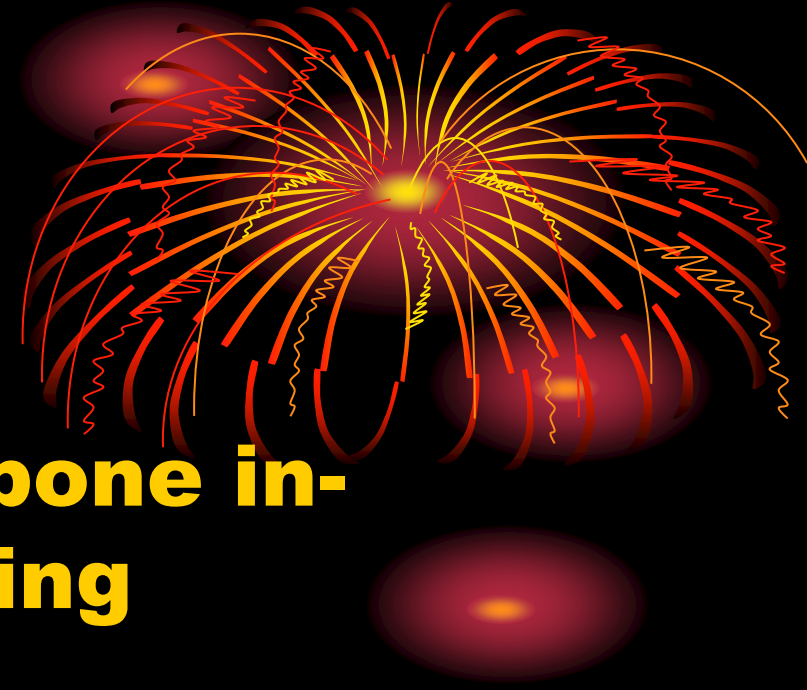Bio-Oss

**an ideal Osteoconductive
Material for use in ridge
preservation**



- **An organic Bovine bone mineral**
- **Maintains chemical composition, crystalline properties, and extensive surface area of bone**
- **Long term safety record**

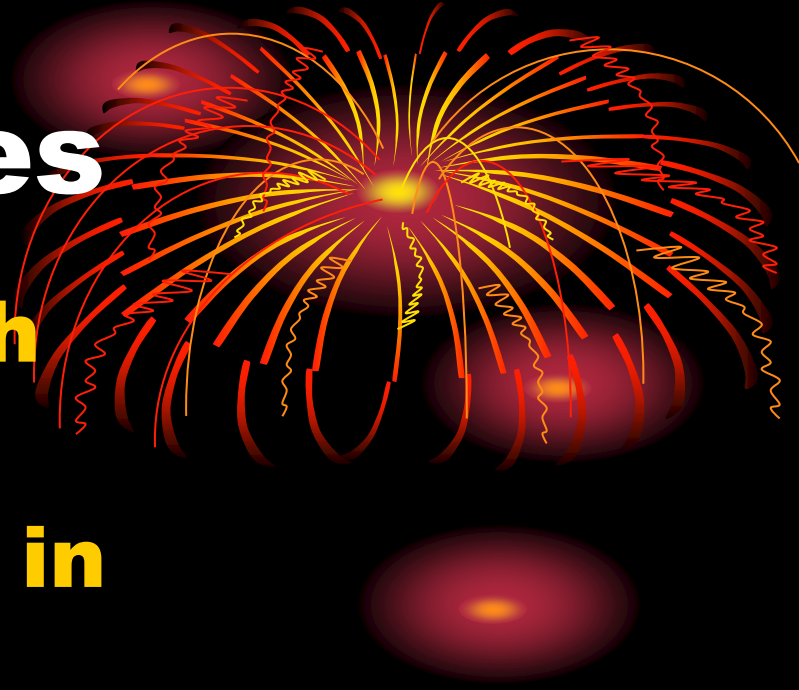Bio-Oss Advantages




- **Hydrophilic material promotes bone ingrowth, resulting in a load bearing composite**
- **Provides inclusive barrier function when mixed with Autogenous bone**
- **Slow substitution rate (perceived disadvantage)**

Bio-Oss Disadvantages

- **May not be compatible with certain religious beliefs**
- **Hydrophilic Material wicks in bacteria**
 - **Keep away from incisions**
 - **Keep within osseous confines of socket**
- **Slow substitution rate**
 - **Material may appear as pebbles or gel upon re-entry following site preservation**

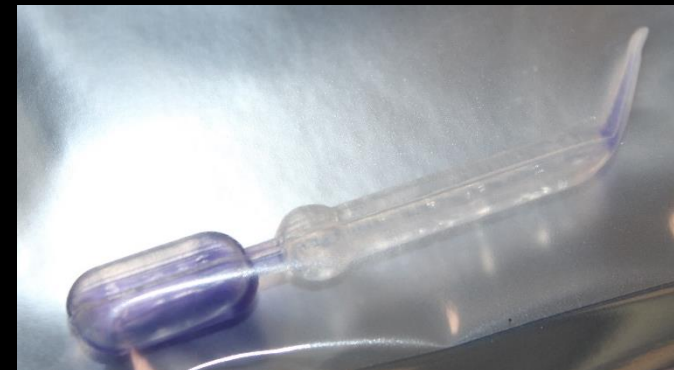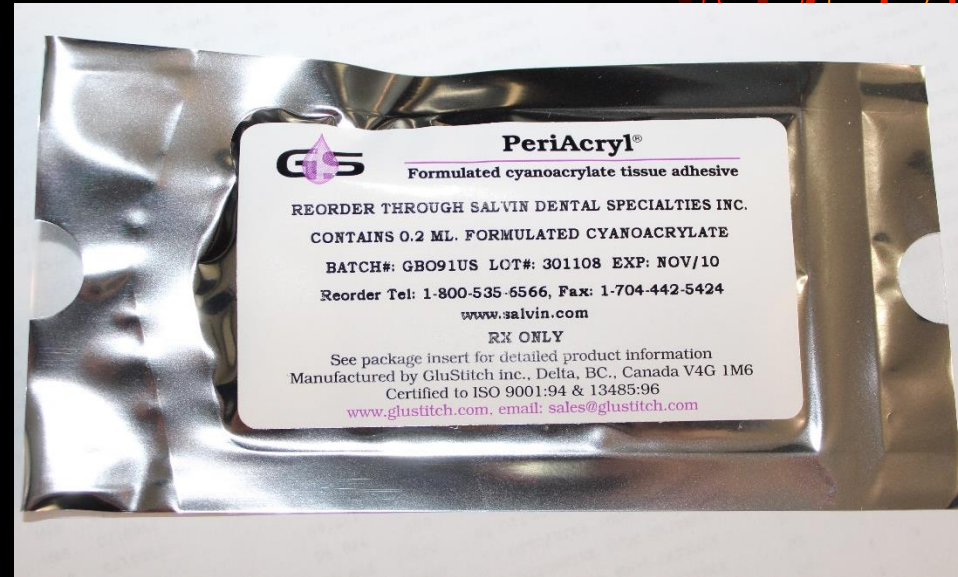

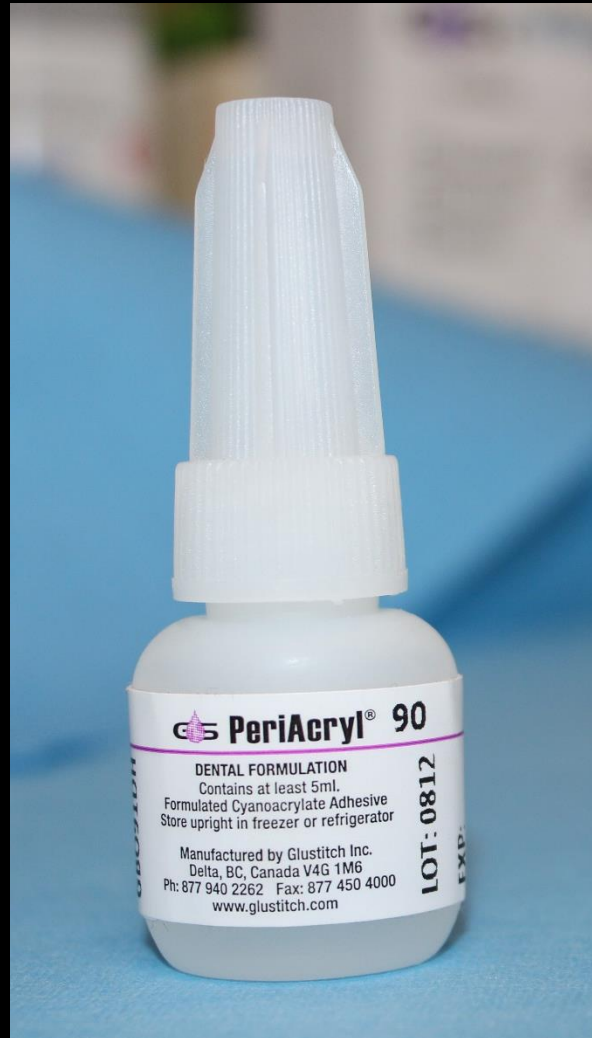
The Bio-Col Procedure



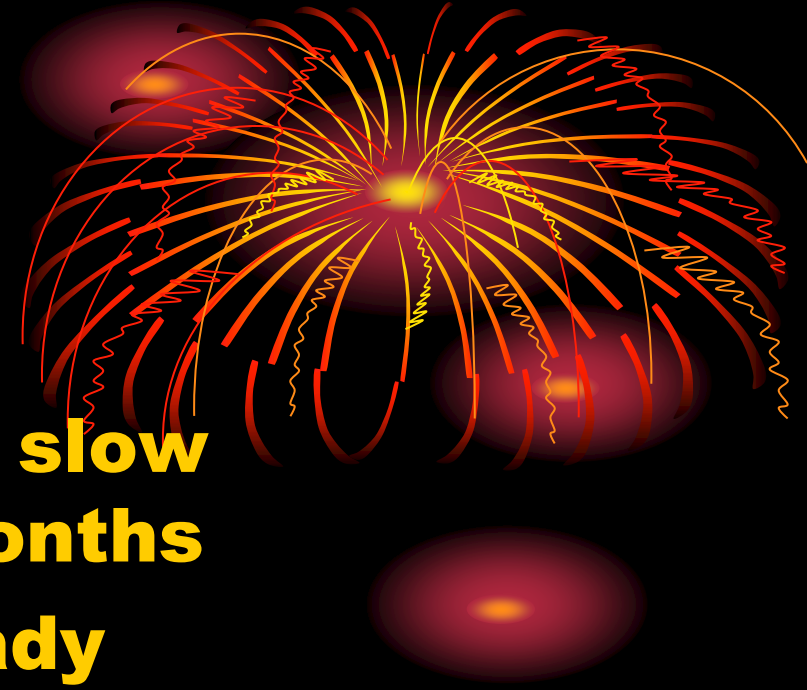- **Atraumatic Extraction !!!!!**
- **Curettement of socket, thorough removal of all granulation tissue and debris & promote bleeding!**
- **Irrigation of socket with Hydrogen Peroxide, Chlorhexidine or Betadine solution(optional)**
- **Placement of Membrane (if class II defect)**
- **Place and pack graft just below gingival crest (2-3 mm)**
- **Place (or fold over) membrane over graft**
- **Suture with plain or chromic gut (3-0 or 4-0)**
- **Seal with tissue glue (PeriAcryl 90 www.glustitch.com)and apply “water” to set glue**
- **Preservation of the tissue support with a pontic, (bonded, removable, or an Essex retainer**

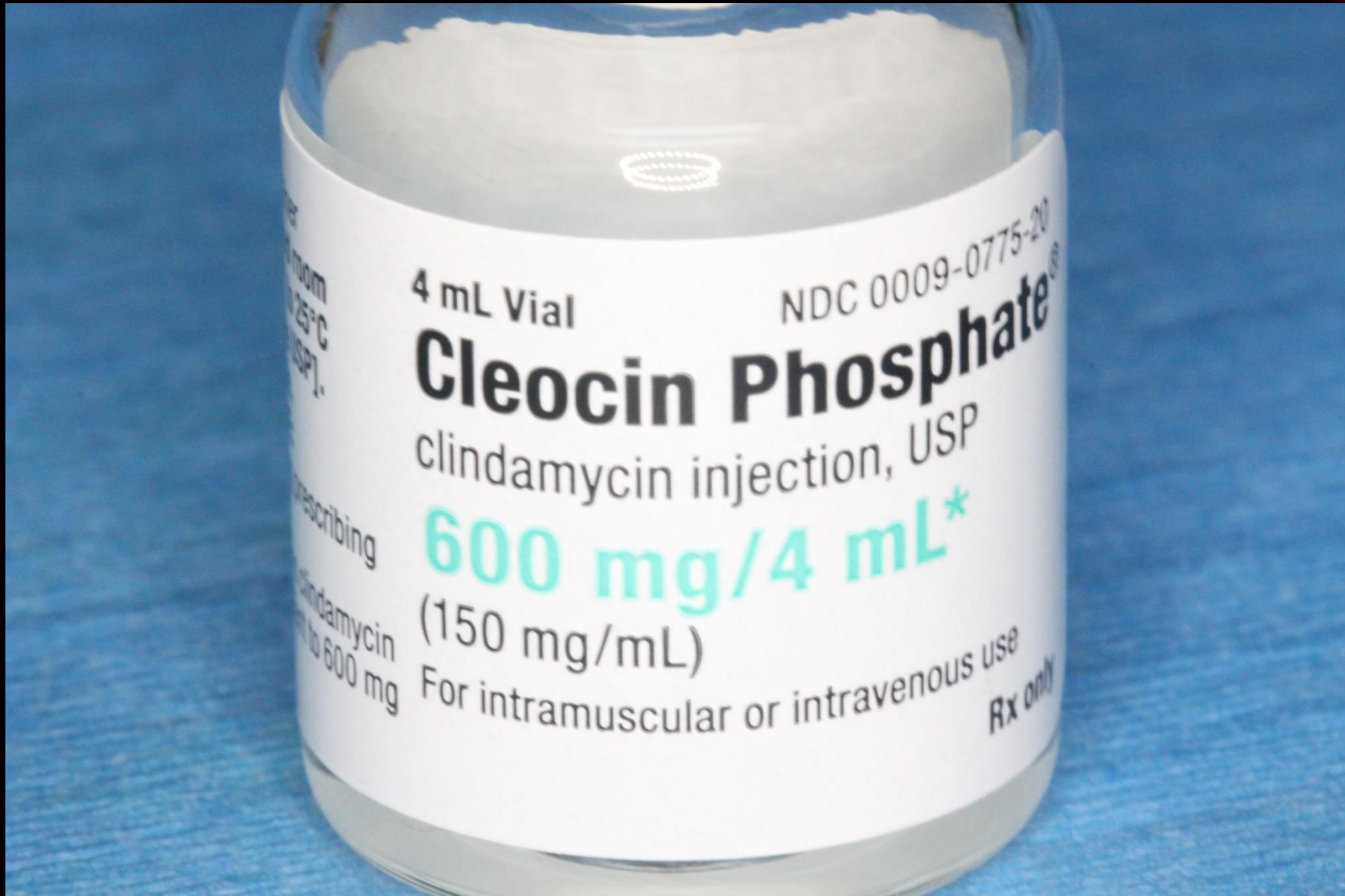
Tissue Glue



Socket Preservation

- **Without membrane**
 - **Use material of choice, prefer slow resorbing material over 3-6 months**
 - **Stimulate bleeding if not already present by “scraping socket”**
 - **Soak graft material with ½ cc of Cleocin or Acef solution (75 mg)**
 - **Cover with 3-4 layers of gel foam membrane**
 - **Suture inside/out figure of eight**
 - **Seal with tissue glue**





NDC 44567-707-25

25 SINGLE USE VIALS

Cefazolin for Injection, USP

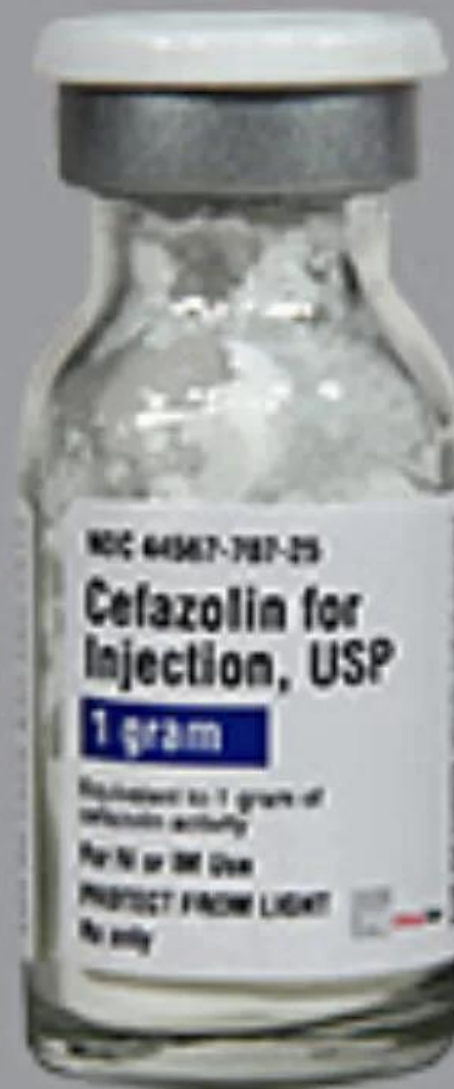
1 gram

Equivalent to 1 gram of cefazolin activity


For IV or IM Use

PROTECT FROM LIGHT


Rx only



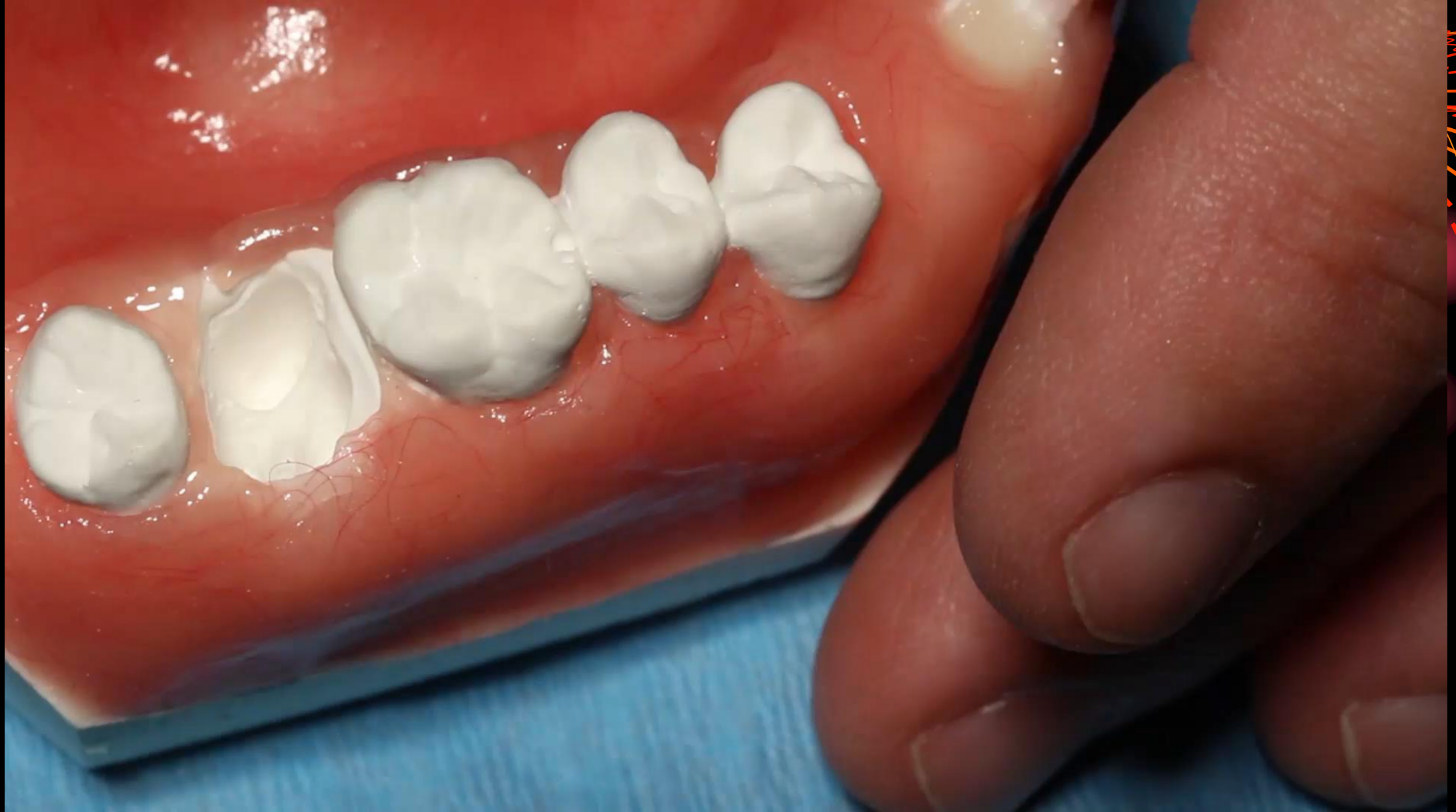Graft material



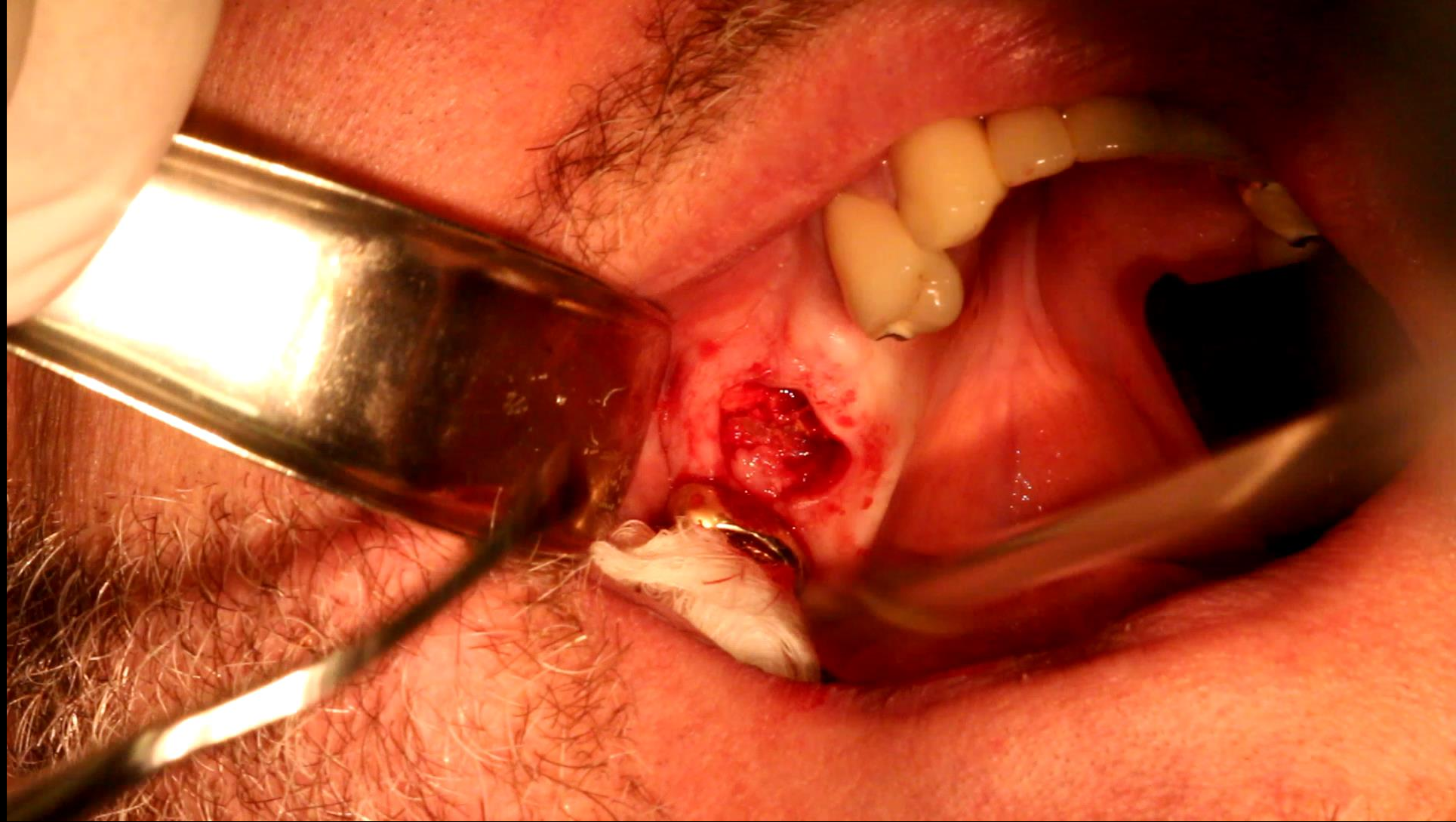
- **Bio-Oss Collagen blocks (Geistlich)**
 - **Crush and shape material to fit into socket and compress with light to moderate force till at boney crest**
- **100mg Block = \$99**
- **250mg Block = \$189**
- **500mg Block = \$325**



Socket Preservation Graft Without Membrane

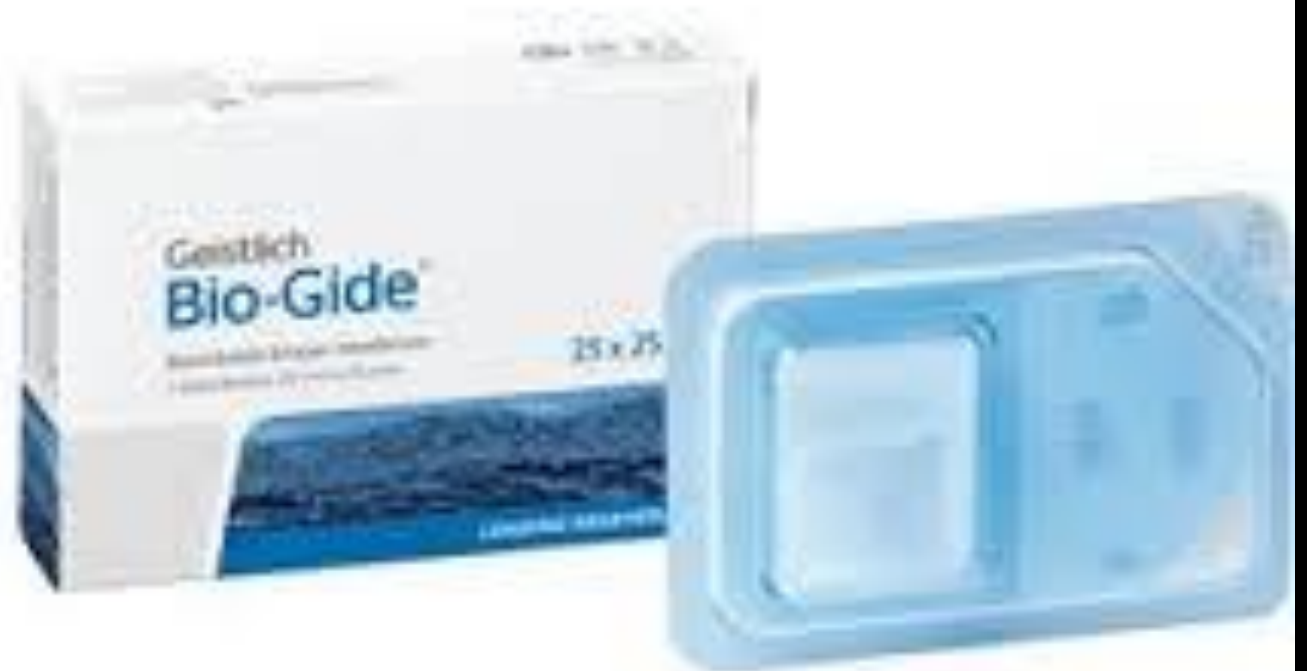
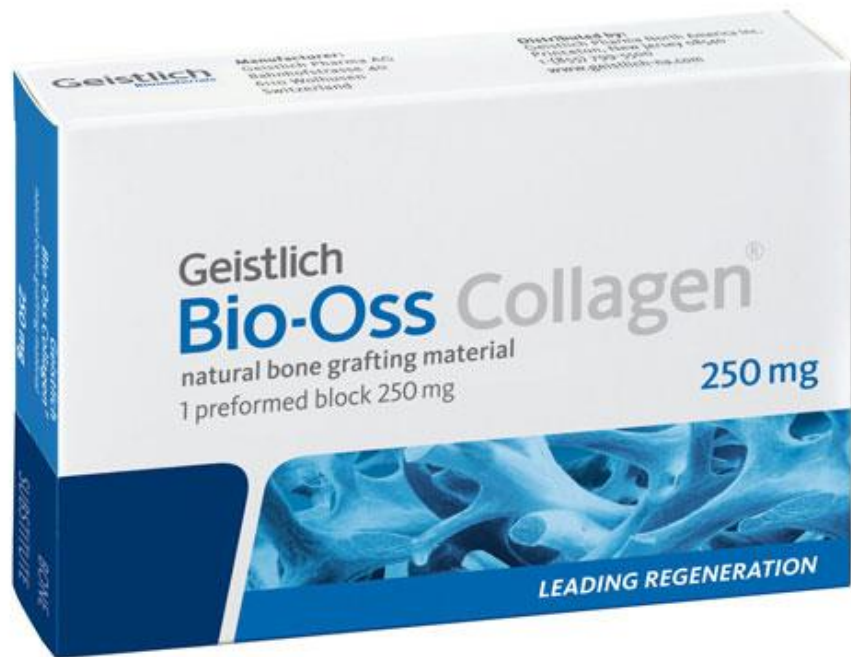


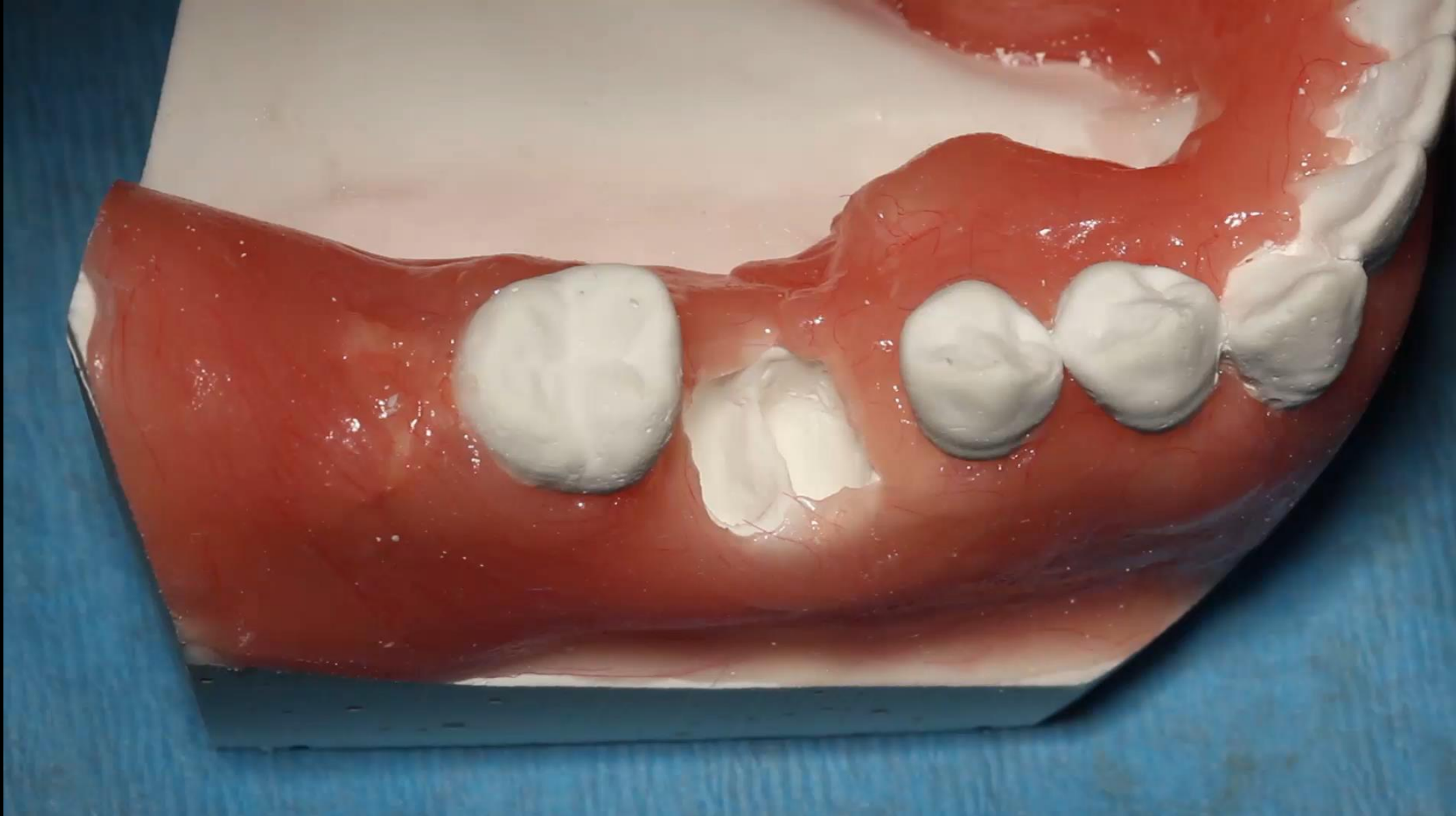Simple Socket Preservation with Gelfoam



Socket Preservation graft with Gelfoam

Socket Preservation Graft with Membrane





Socket Preservation Graft with membrane

Soft Tissue Impaction

Ideal Case Selection:


Vertical or slight mesial angle impaction

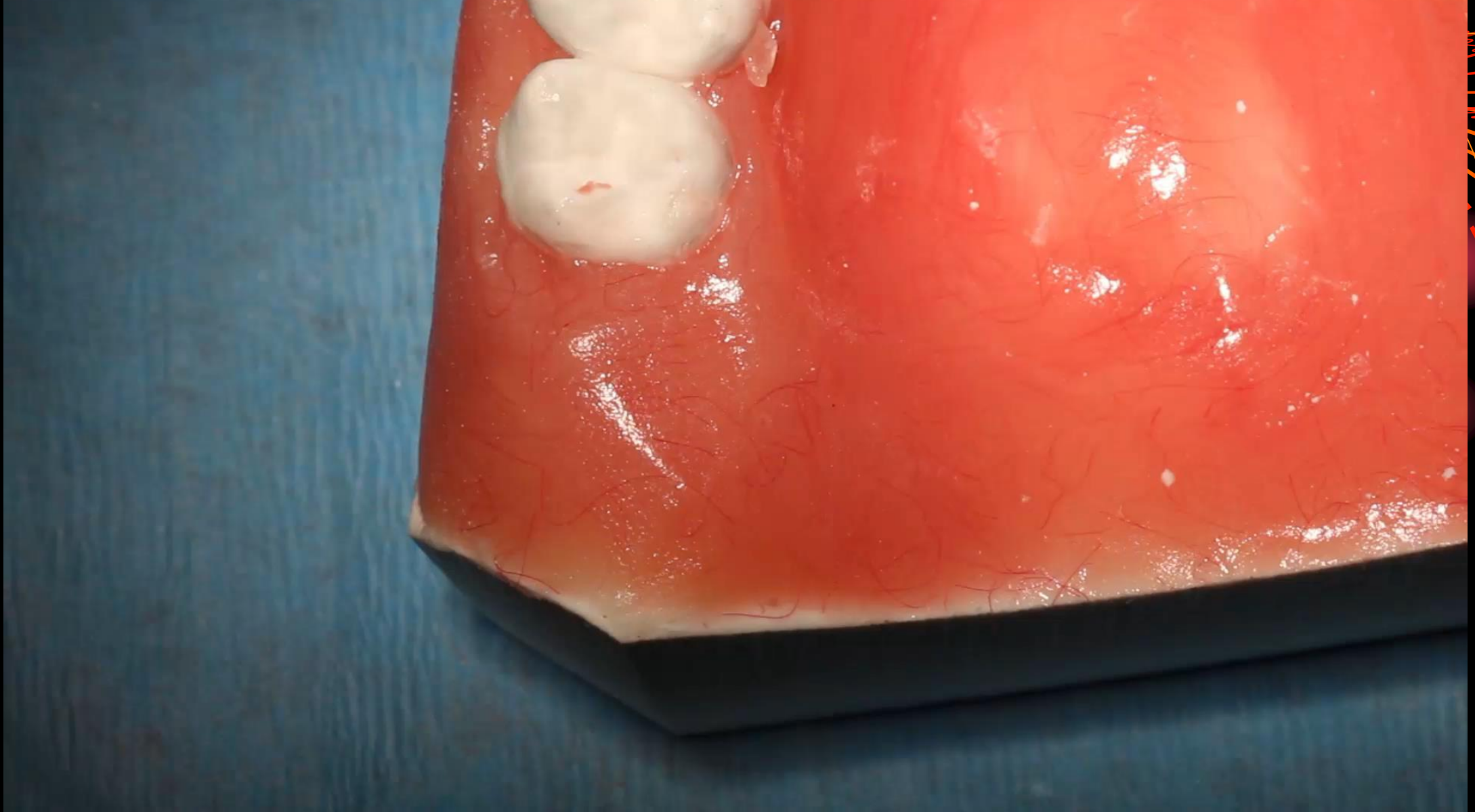
3/4 to almost fully developed tooth (usually under 25 Y.O.)

Cone shaped root structure

Minimal flap design



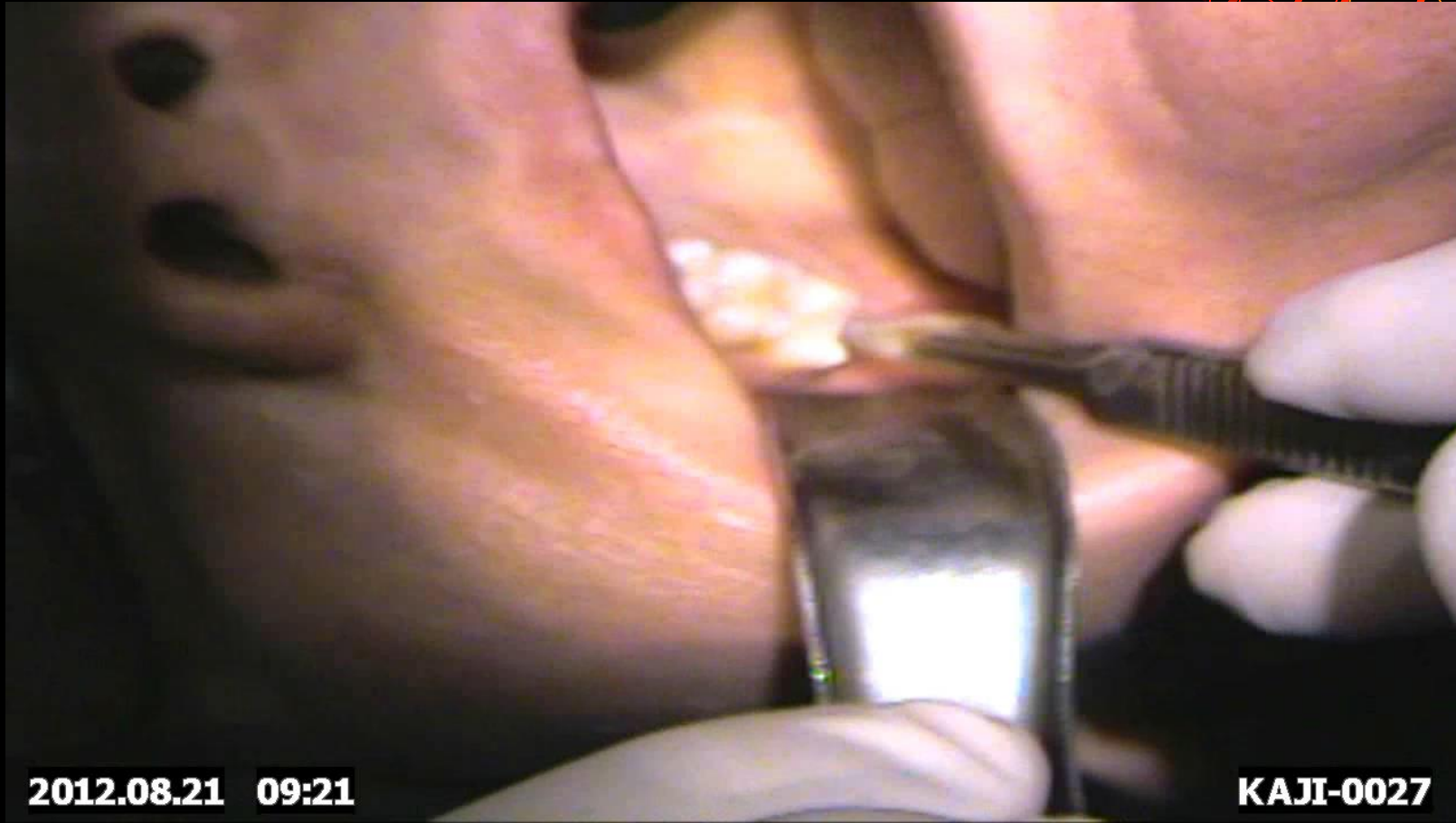
Look and feel for the “MAGIC SPOT” !!!!!!!





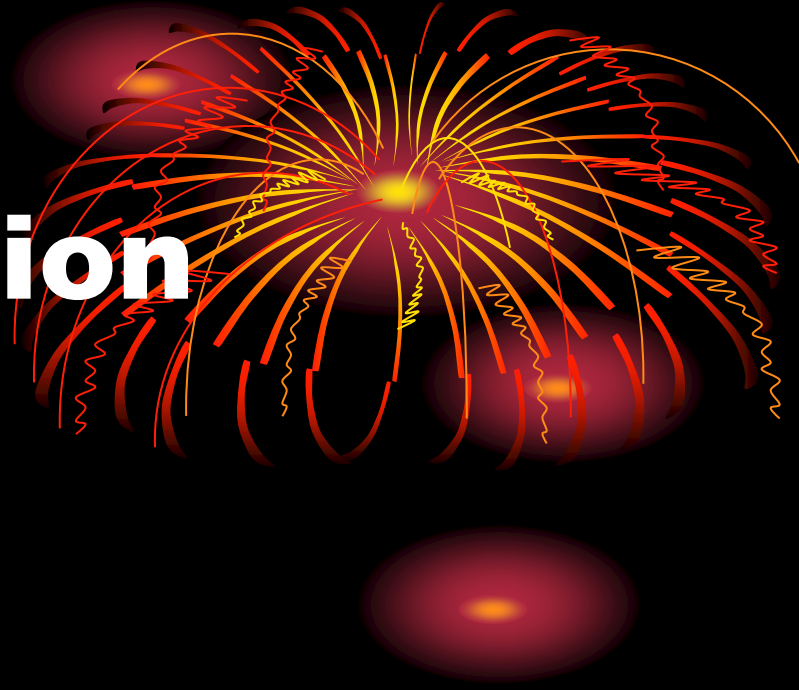Soft Tissue Impaction #1

Soft tissue Impaction



Partial Boney Impaction

#32



Ideal Case Selection:

Vertical or slight mesial angle impaction

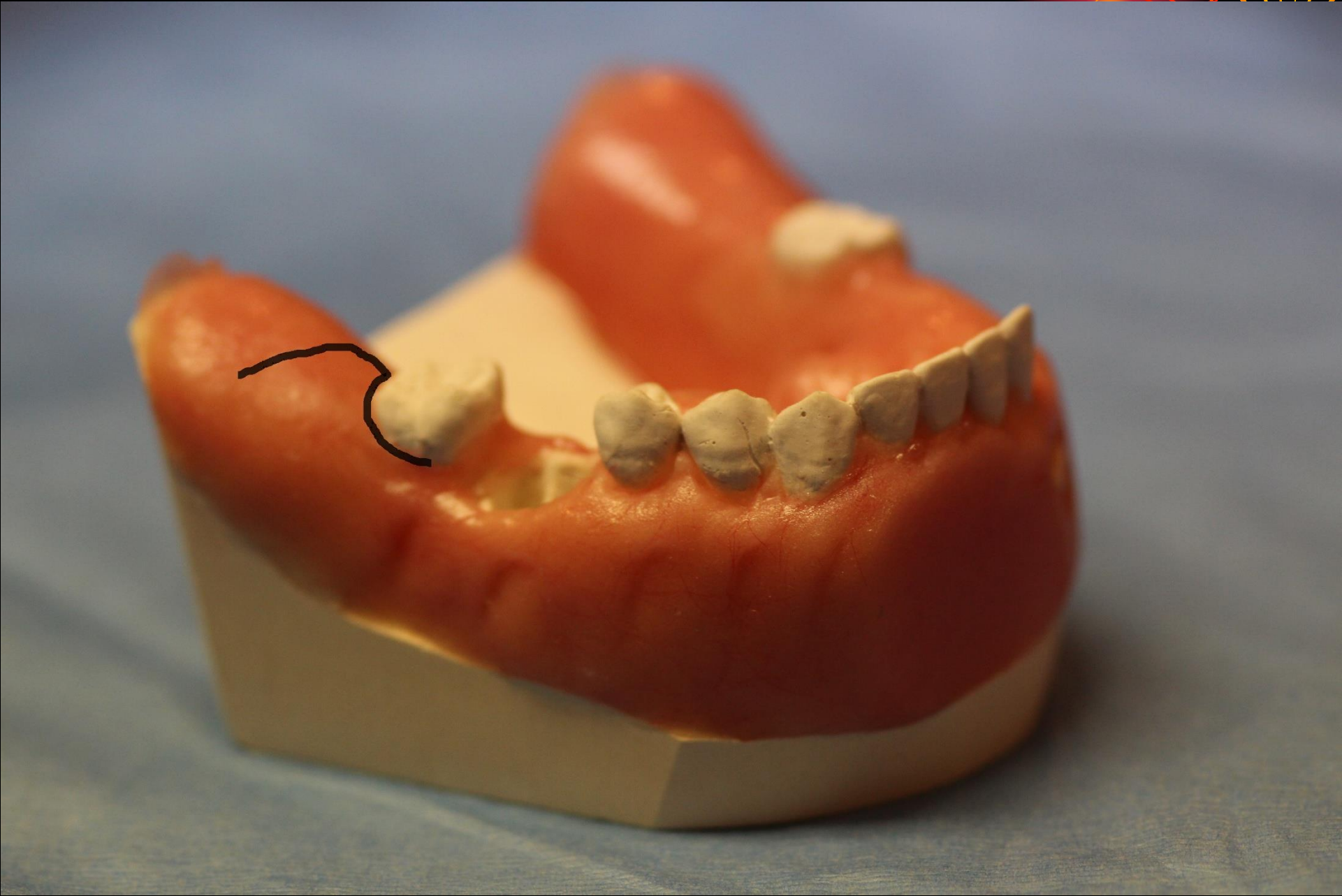
3/4 to almost fully developed tooth (usually under 25 Y.O.)

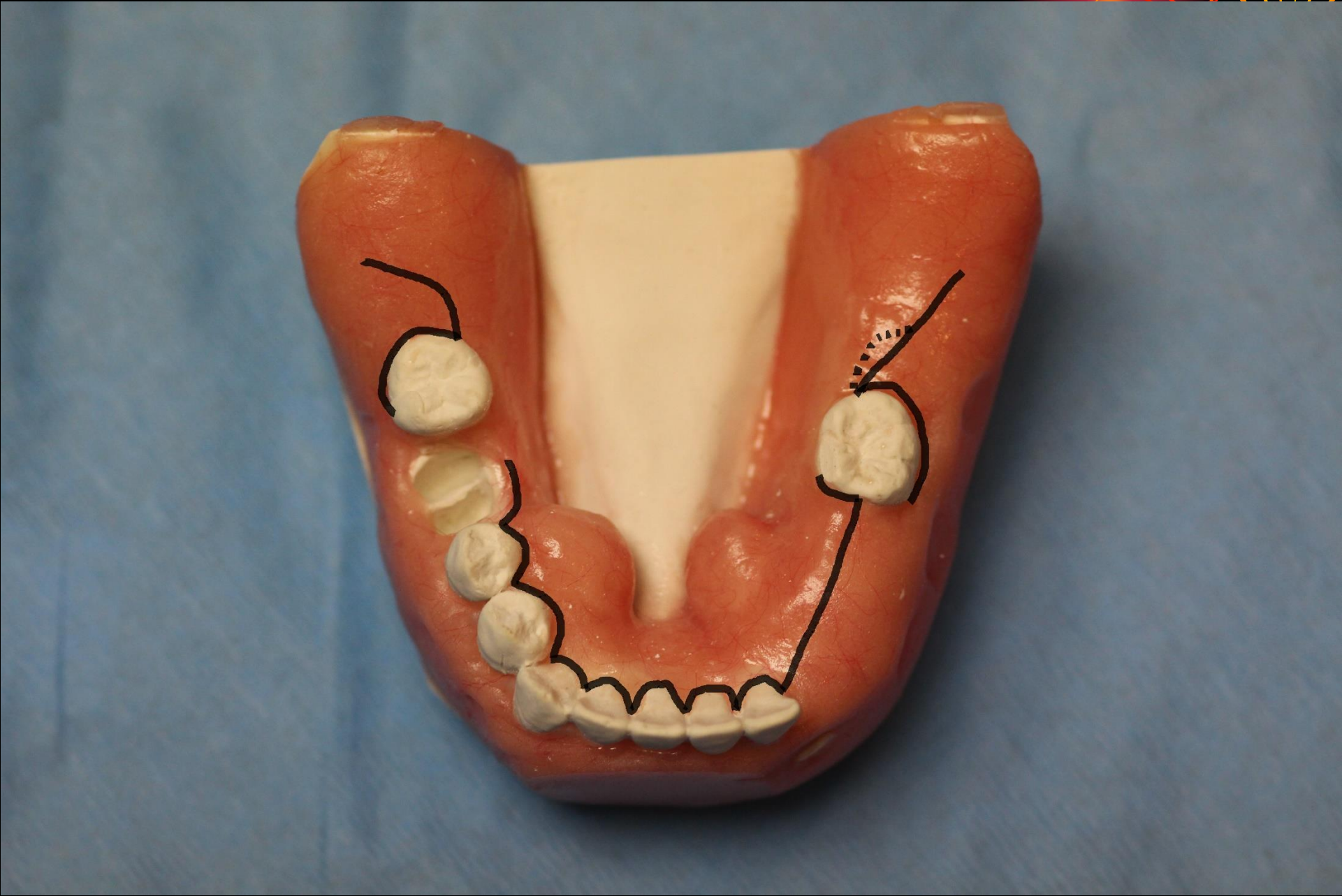
Cone shaped root structure

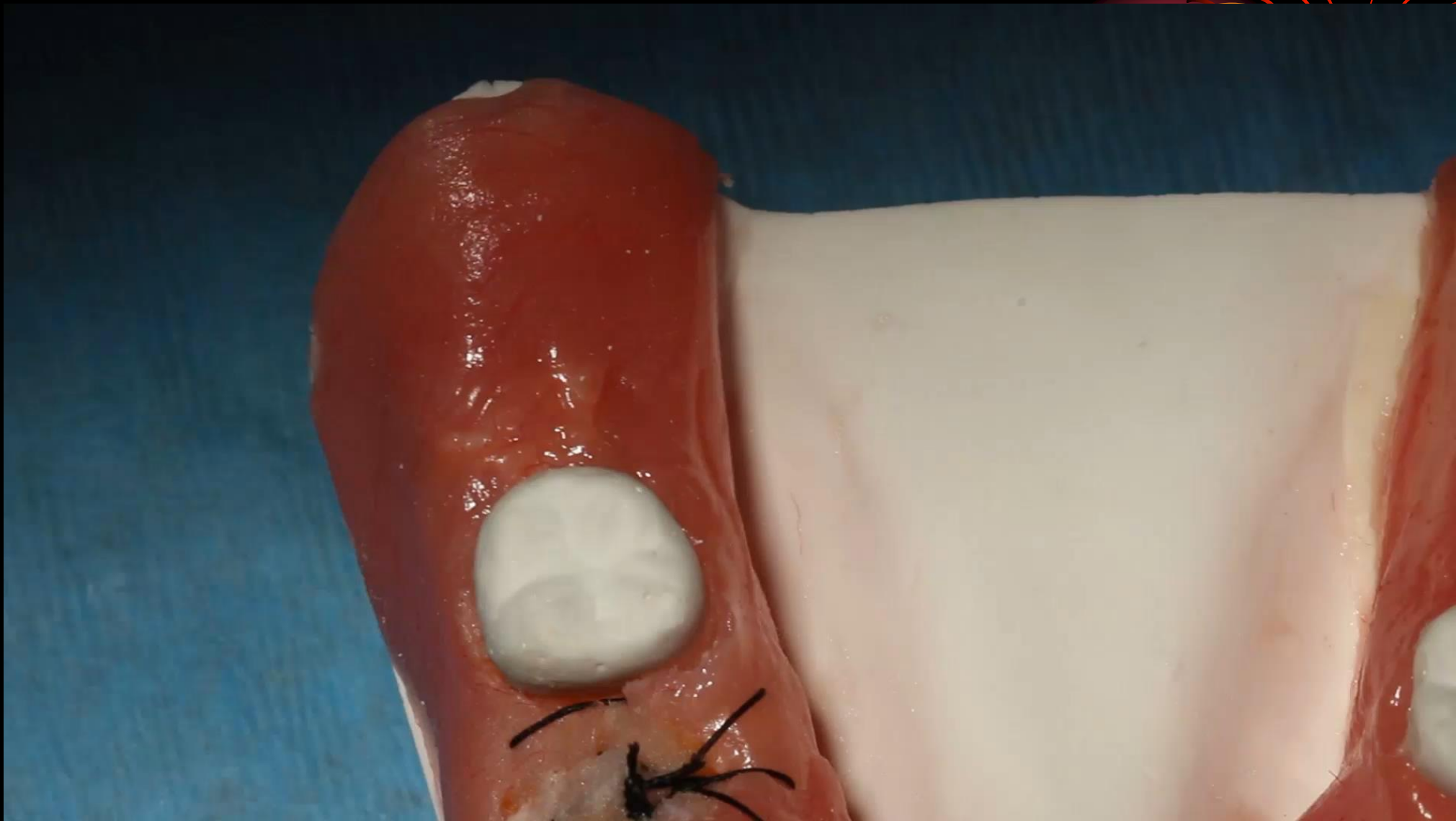Minimal flap design

Bone removal with elevator or handpiece

Look and feel for the “MAGIC SPOT” !!!!!!!



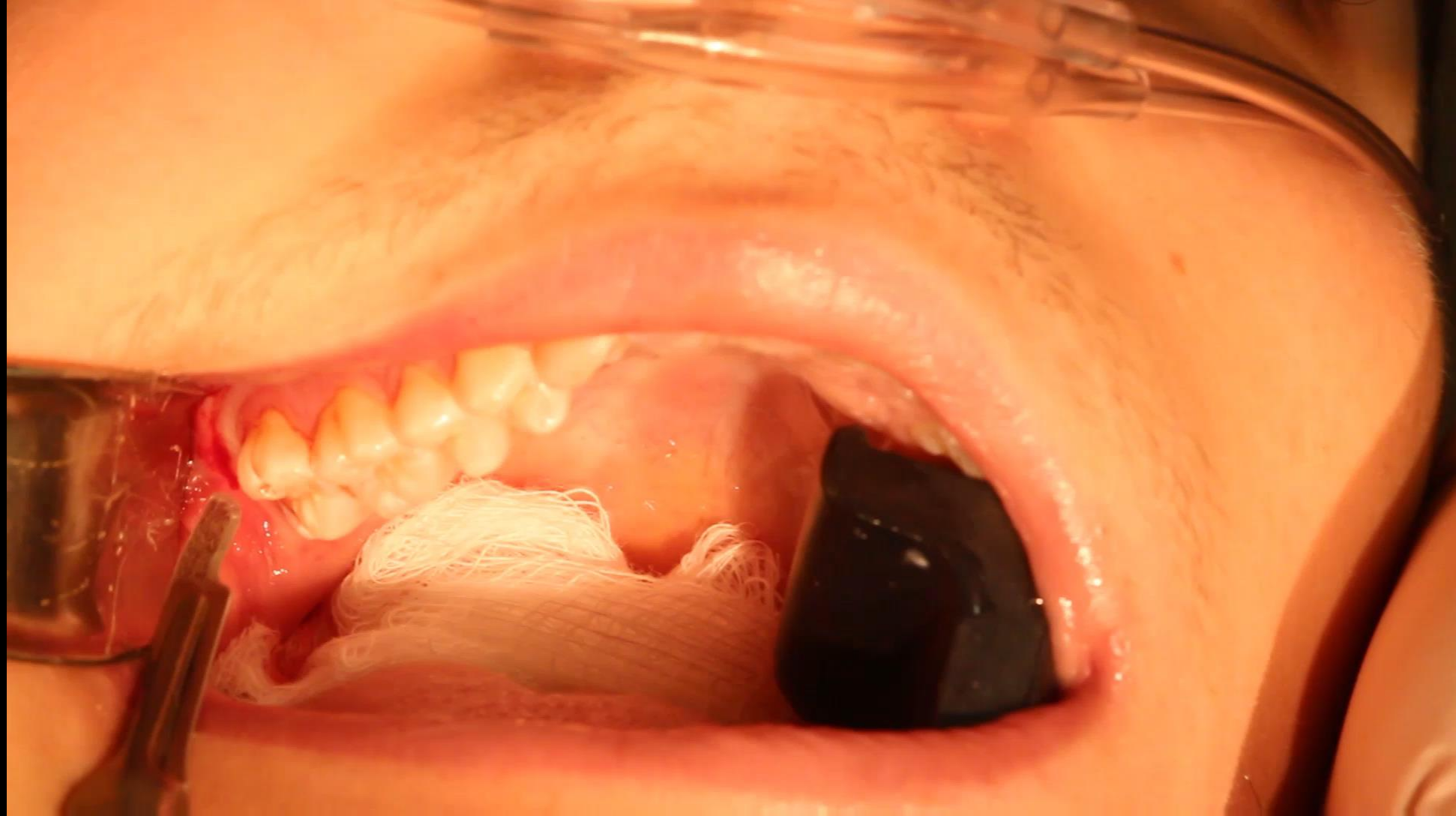





Partial Boney impaction Tooth #32

**Wisdom Teeth Extraction
Partial Boney / Soft Tissue
Live Surgery**





**Wisdom Teeth Extraction
Partial Boney / Soft Tissue**

Complete Boney Horizontal Impaction #17

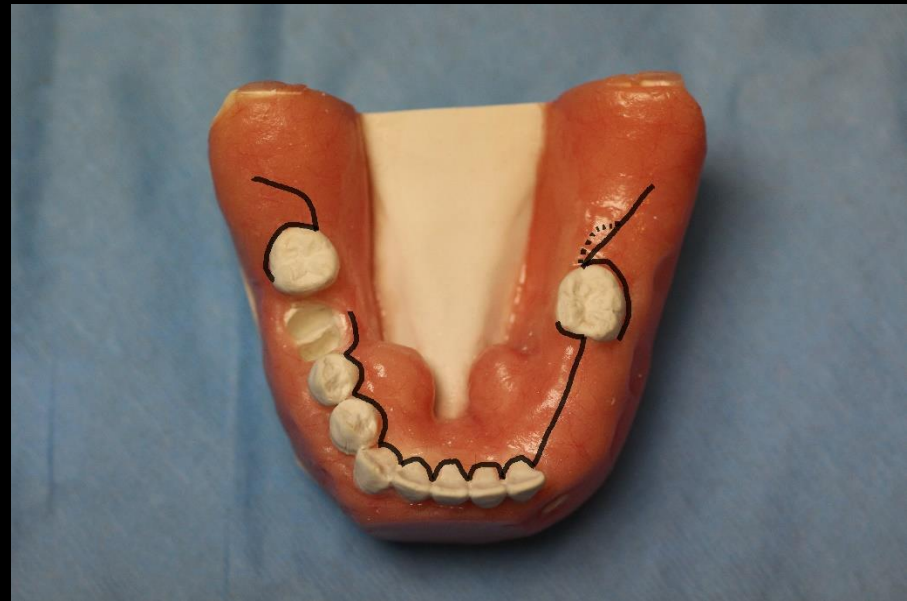
Flap design:


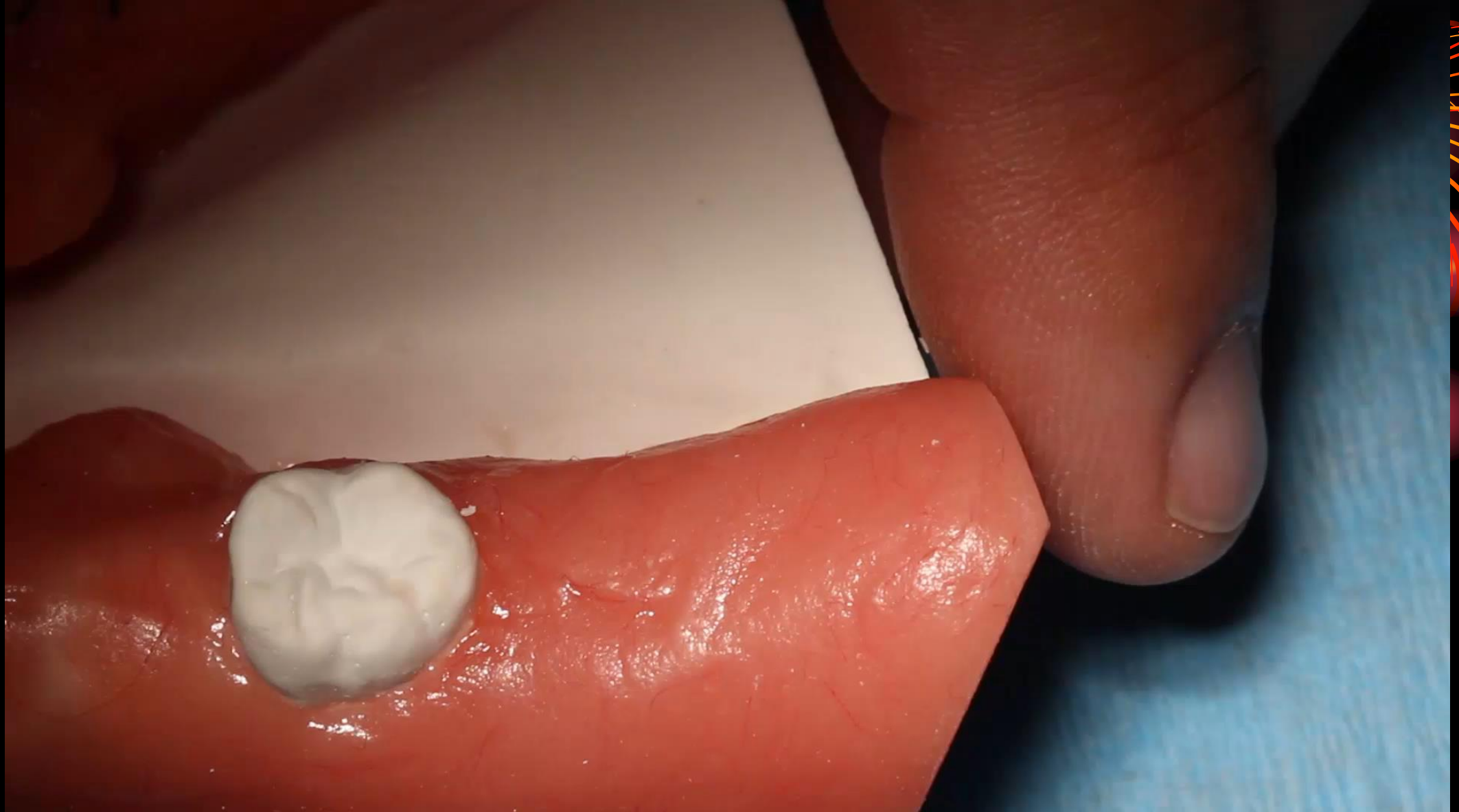
“hockey stick” envelope without release

Angle laterally from 2/3 the distance to DL line angle

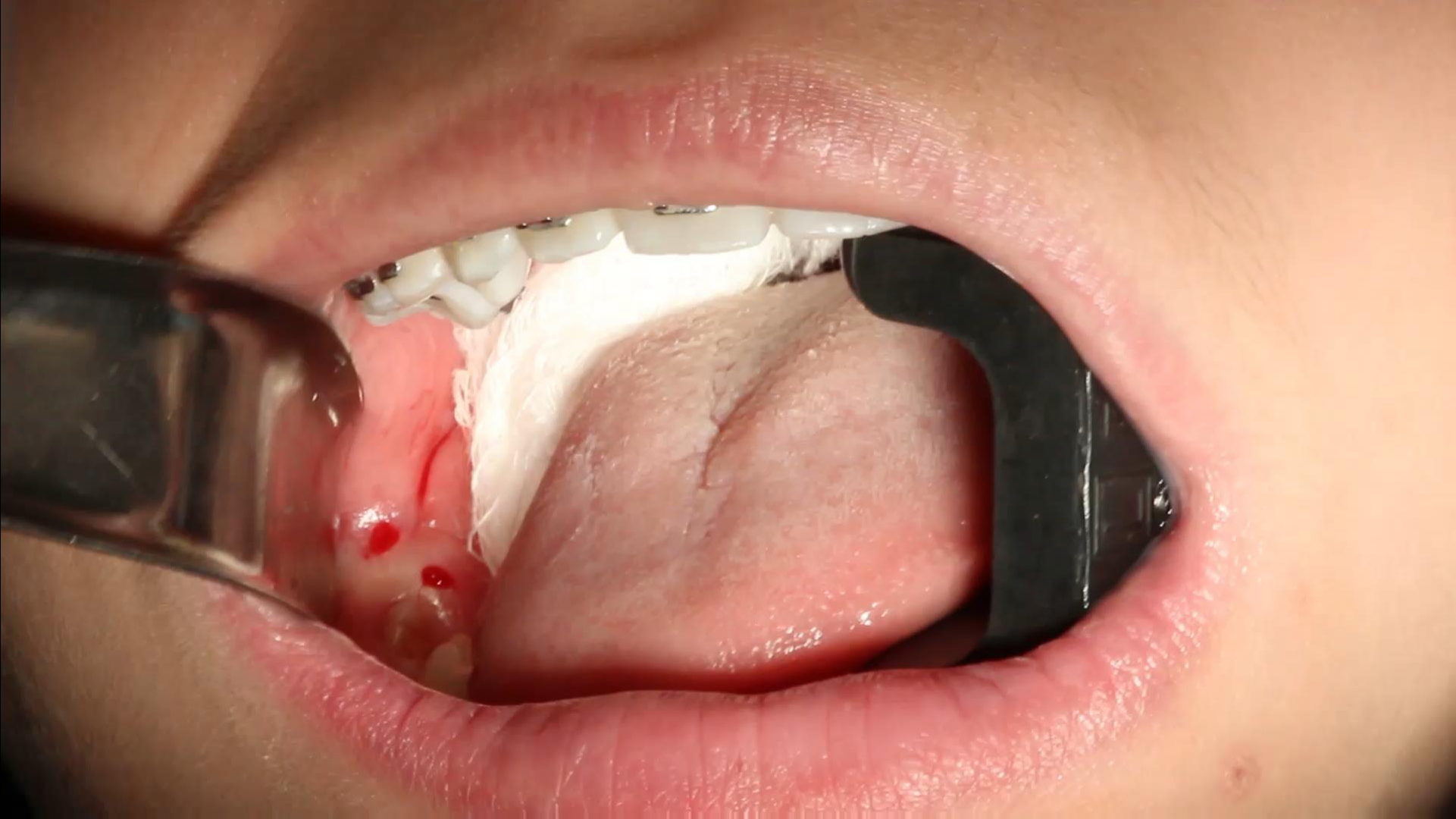
“feel for the tooth” with the blade

Release the incision if necessary on mesial






CB Horizontal impaction #17



CB Horizontal Impaction (Live)

Maxillary Palatal tori

- **HS drill with #1703 surgical bur**
- **Woodson periosteal elevator**
- **Flat osteotomes and mallet**
- **Large ronguers & #150 forceps**
- **4-0 plain gut suture**
- **Optional stent or denture with soft tissue conditioner**

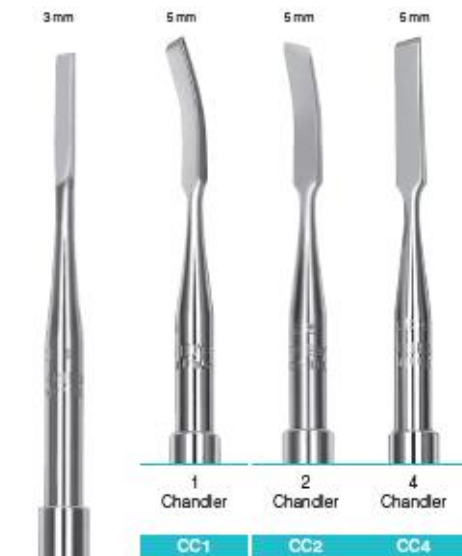

BONE CHISELS

Used to section teeth and/or split, widen the split or remove bone.

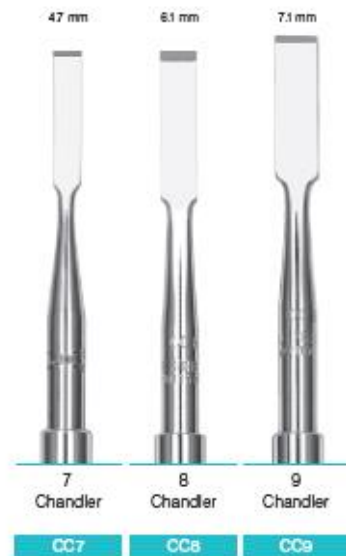SINGLE BEVEL

Used to shave bone





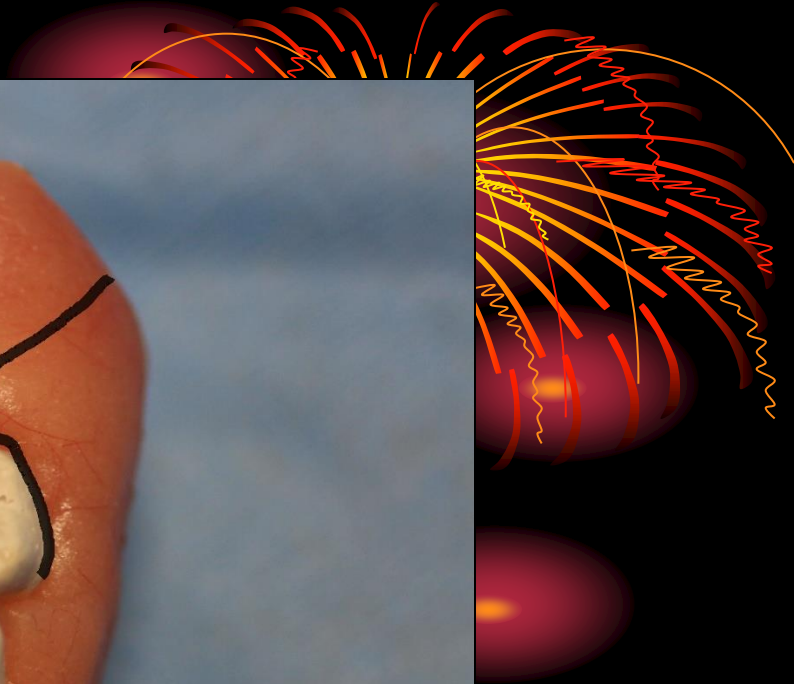
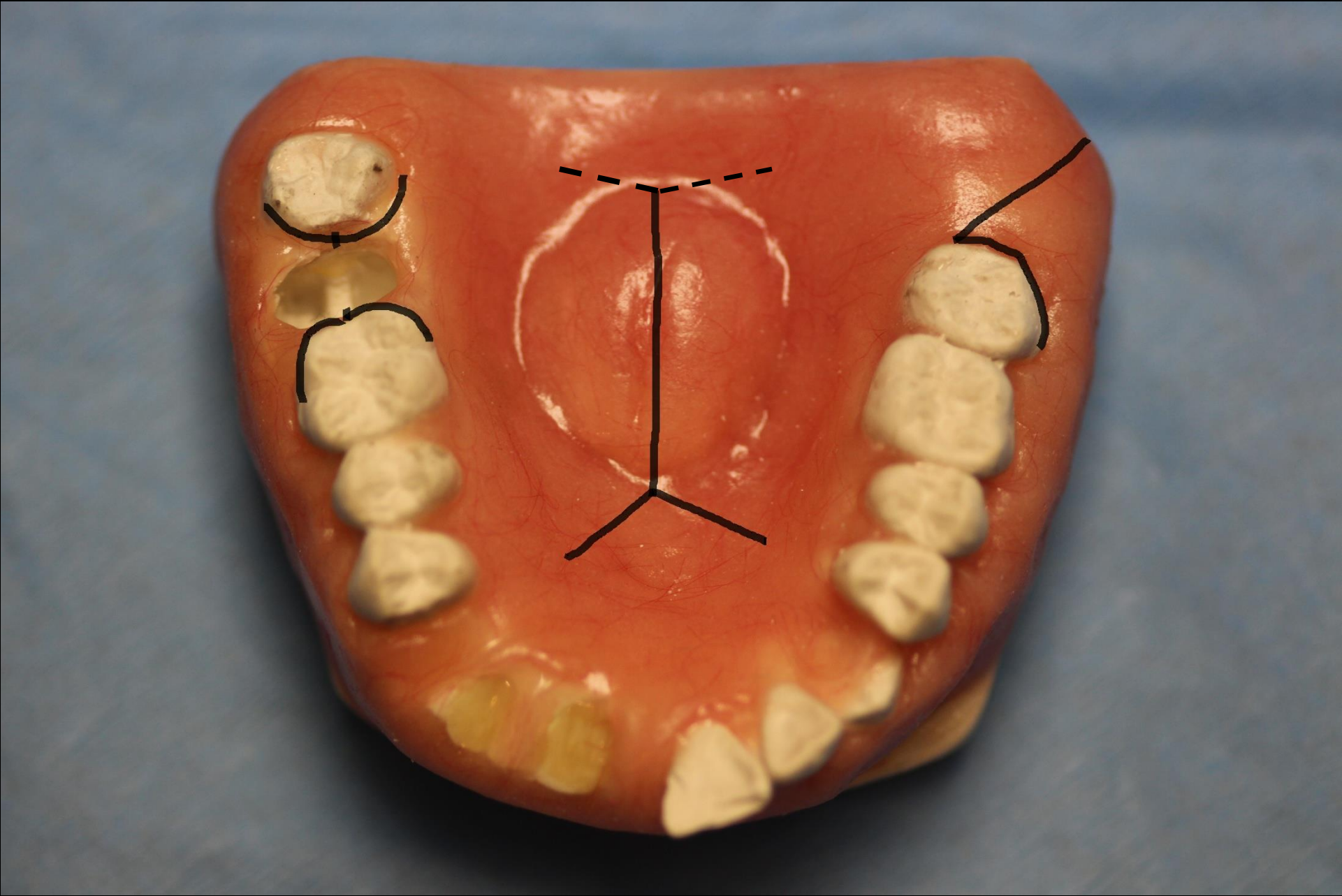
BI-BEVEL

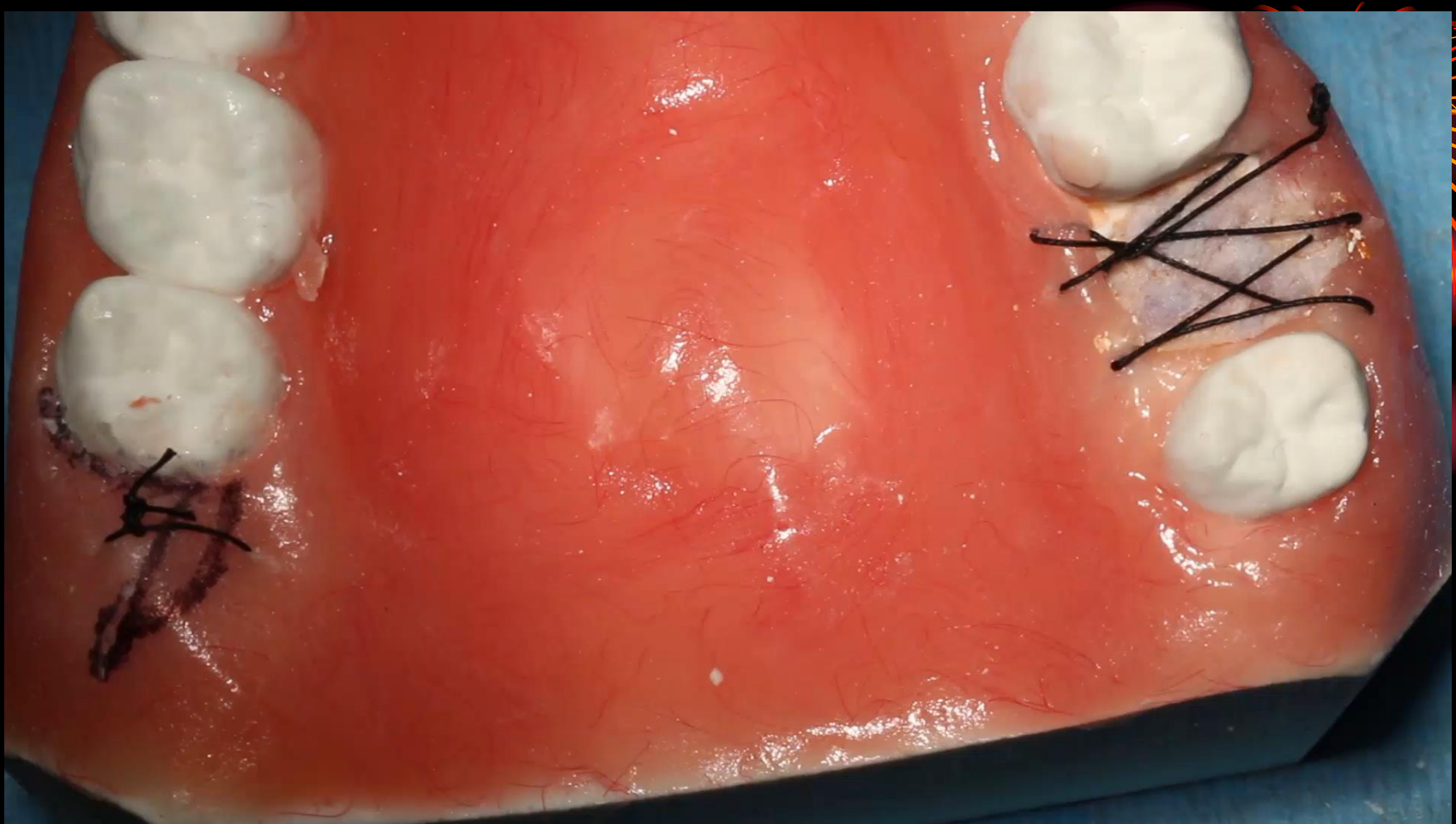Used for splitting teeth



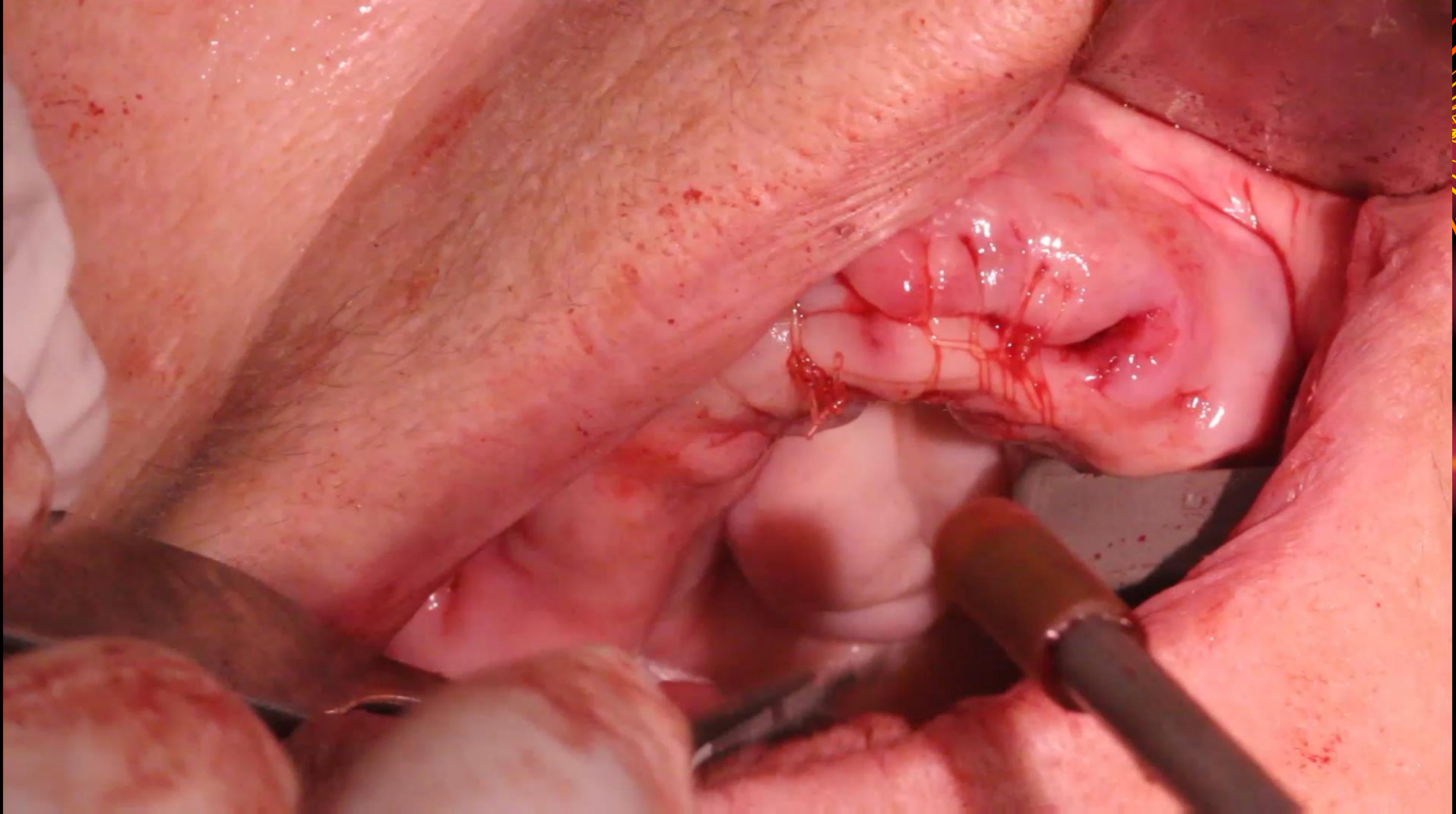
GOUGE









Maxillary Palatal Tori

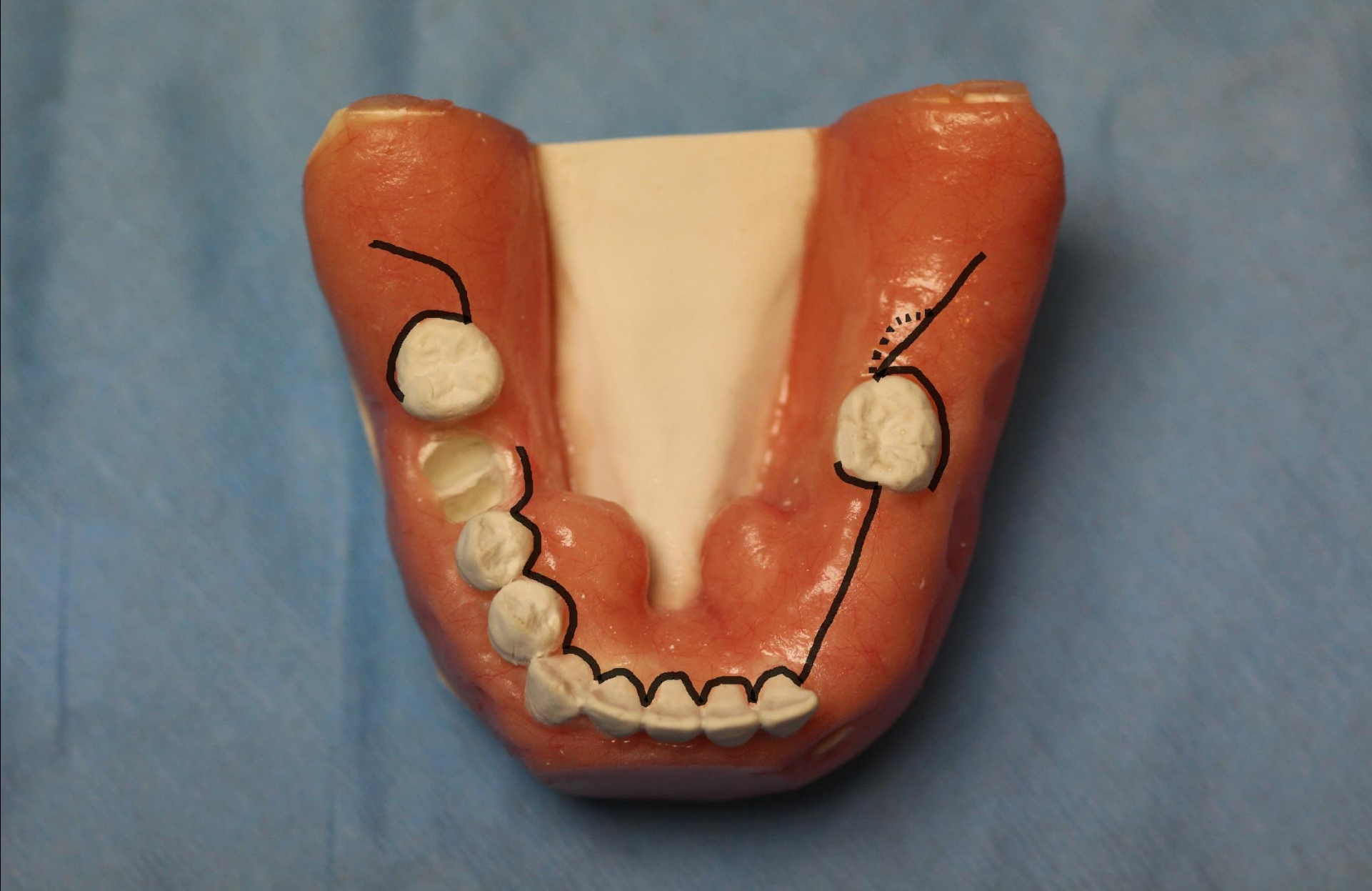


Maxillary Palatal Tori (Live Demonstration)

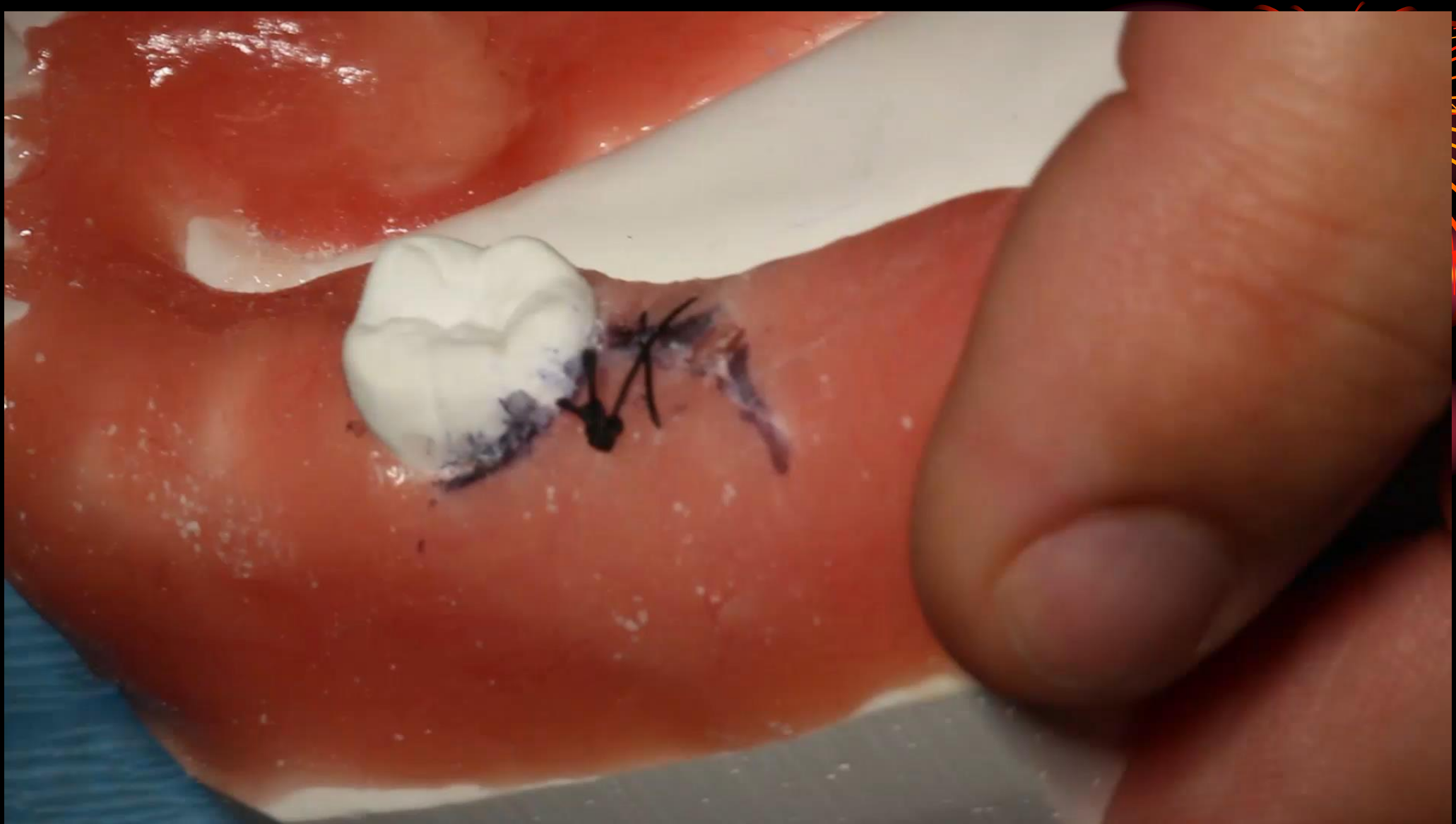Mandibular Lingual Tori

- **Sulcular Incision with 12-B blade**
- **Extension into papilla**
- **Length one tooth on either side of tori, and usually to midline**
- **Slow, careful removal of tissue**
- **Score/trough with #1701 bur**
- **Fracture off tori with osteotome**
- **Continuous running 3-0 p-gut suture**



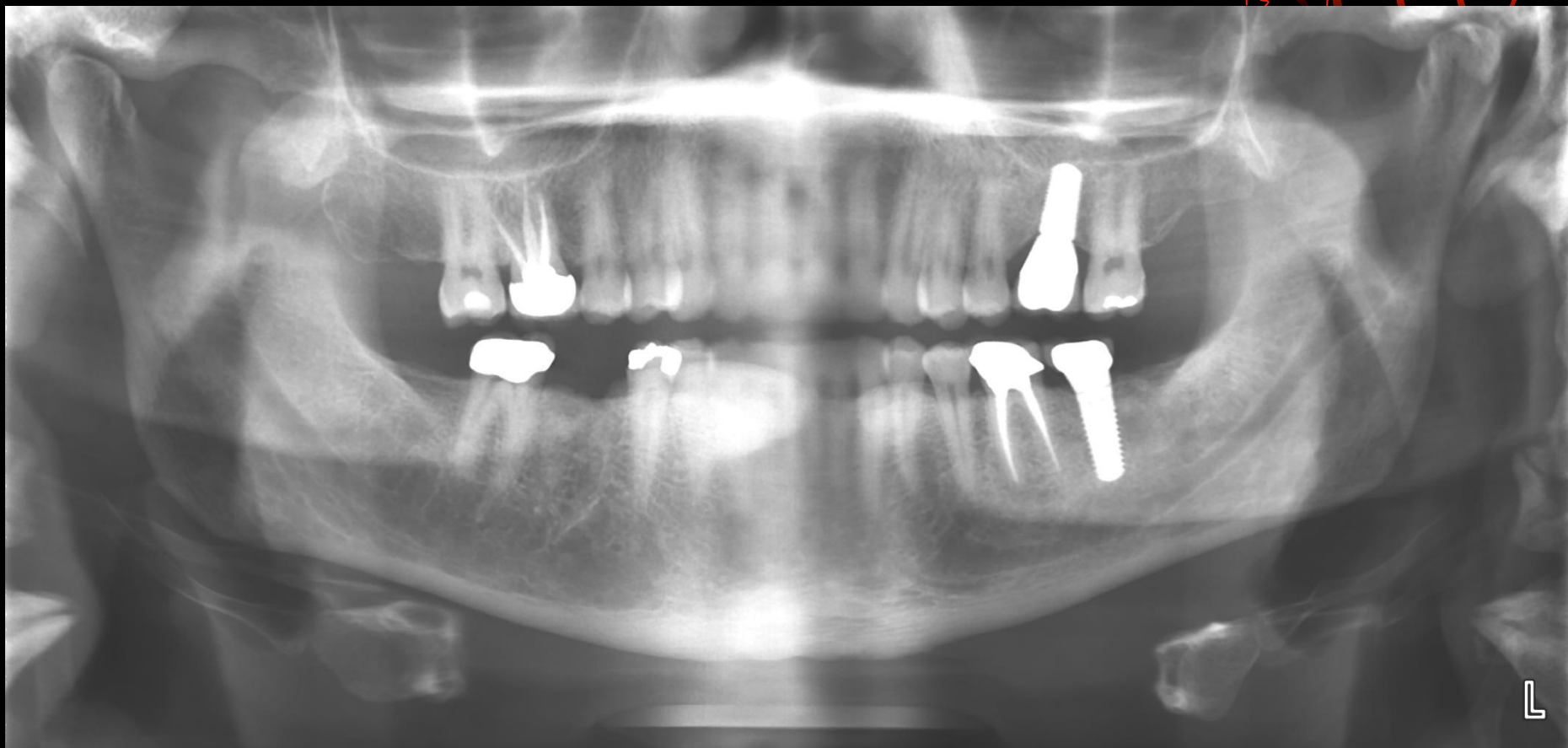


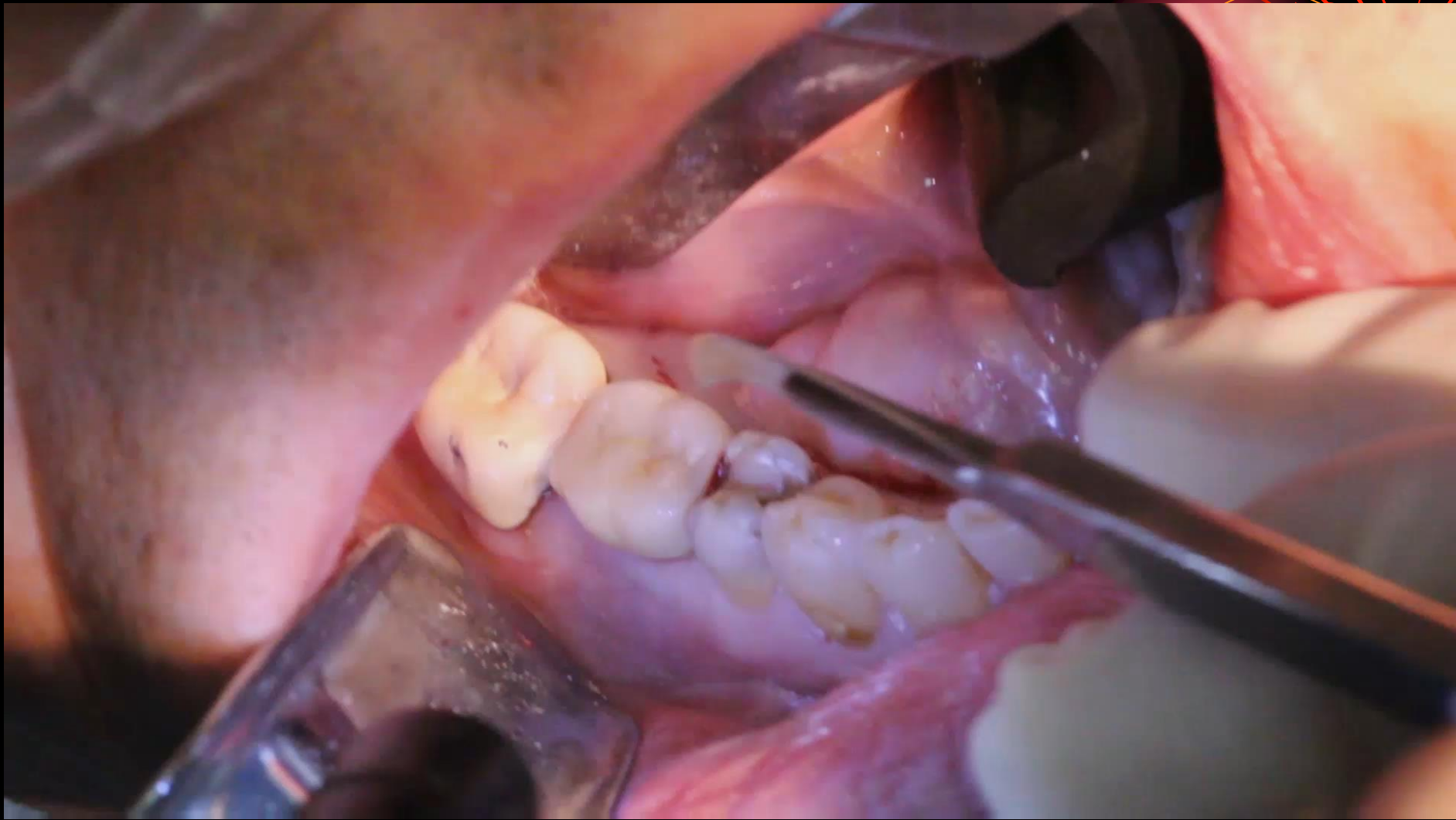
Mandibular Lingual Tori



Mandibular Lingual Tori

Mandibular Lingual Tori (Live Demonstration)



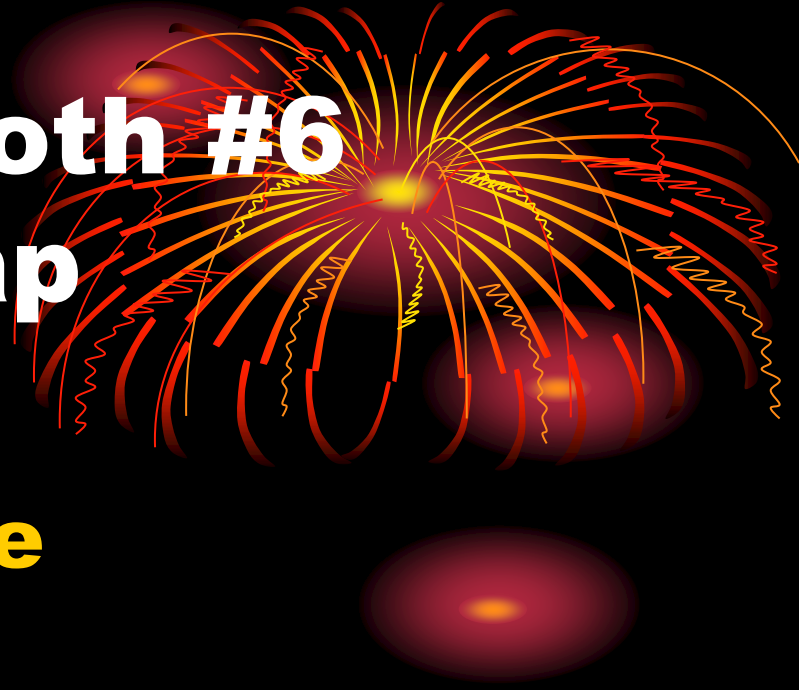


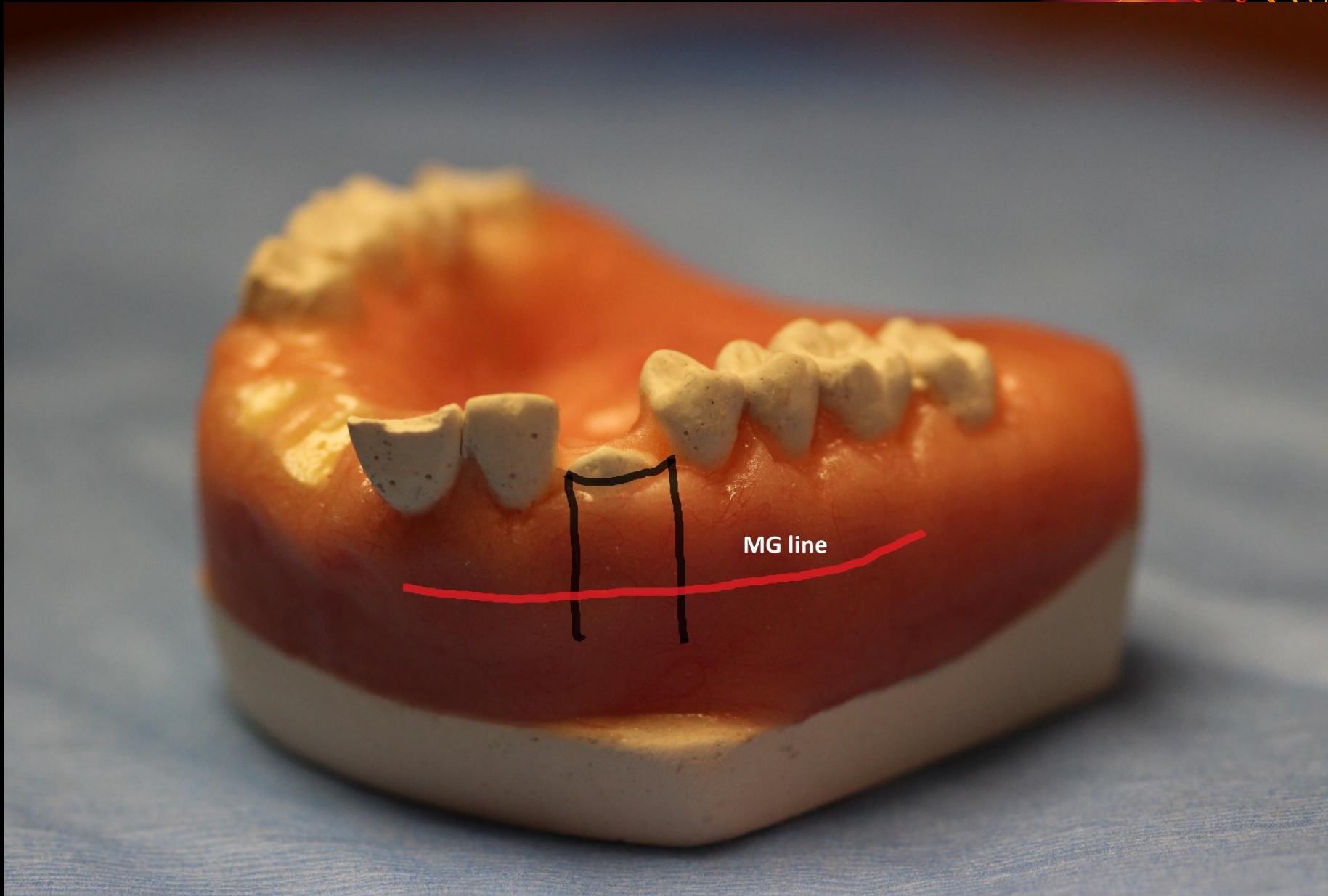
Mandibular Lingual Tori (Live Demonstration)

Soft Tissue exposure tooth #6


Apically repositioned flap

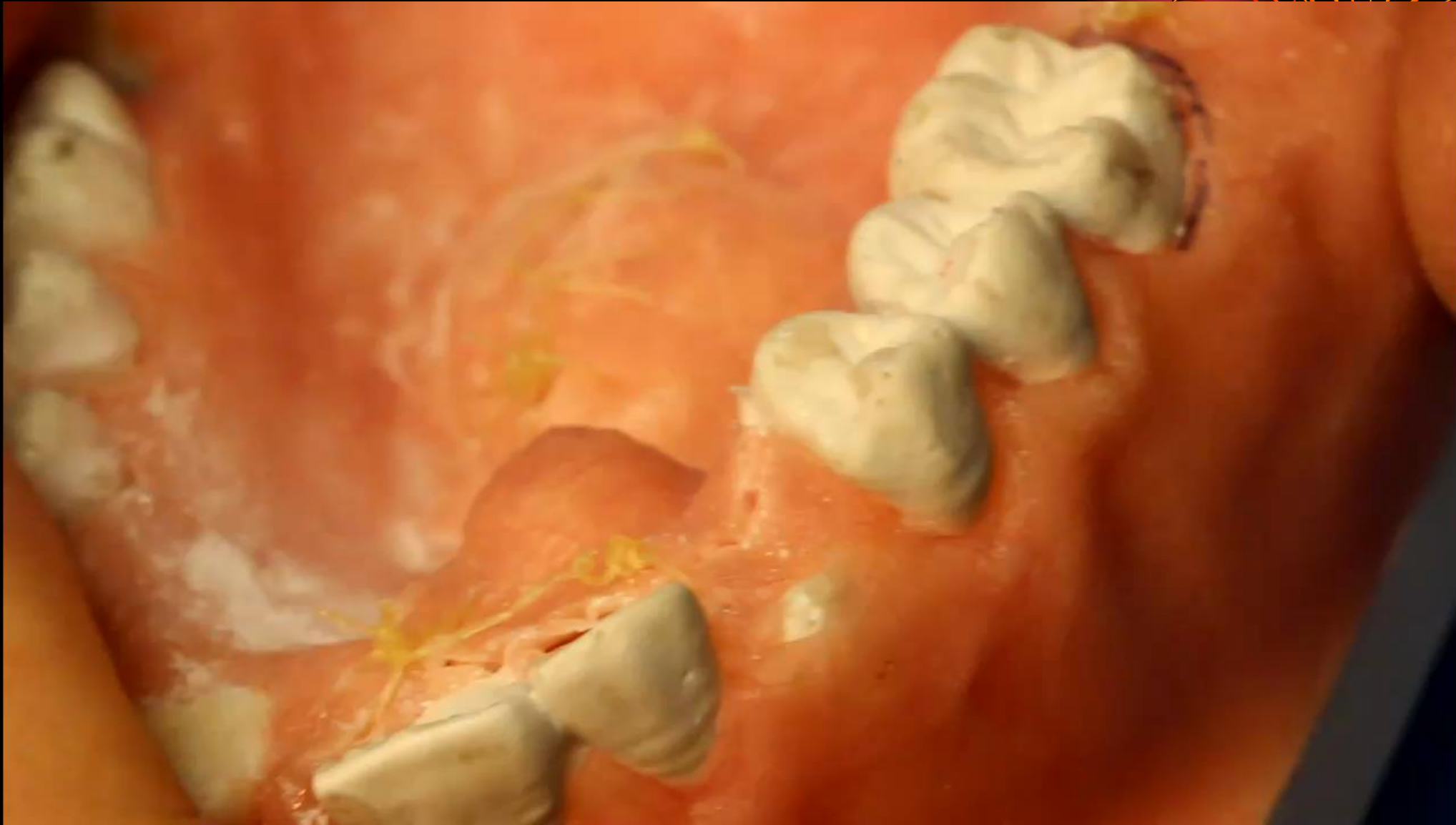- **Vertical parallel Incisions**
- **Extension apically below the mucogingival junction**
- **Split interproximal papilla**
- **Release periosteum below M-G junction**
- **Leave excessive tissue folded, although it can be done as a free graft**





MG line




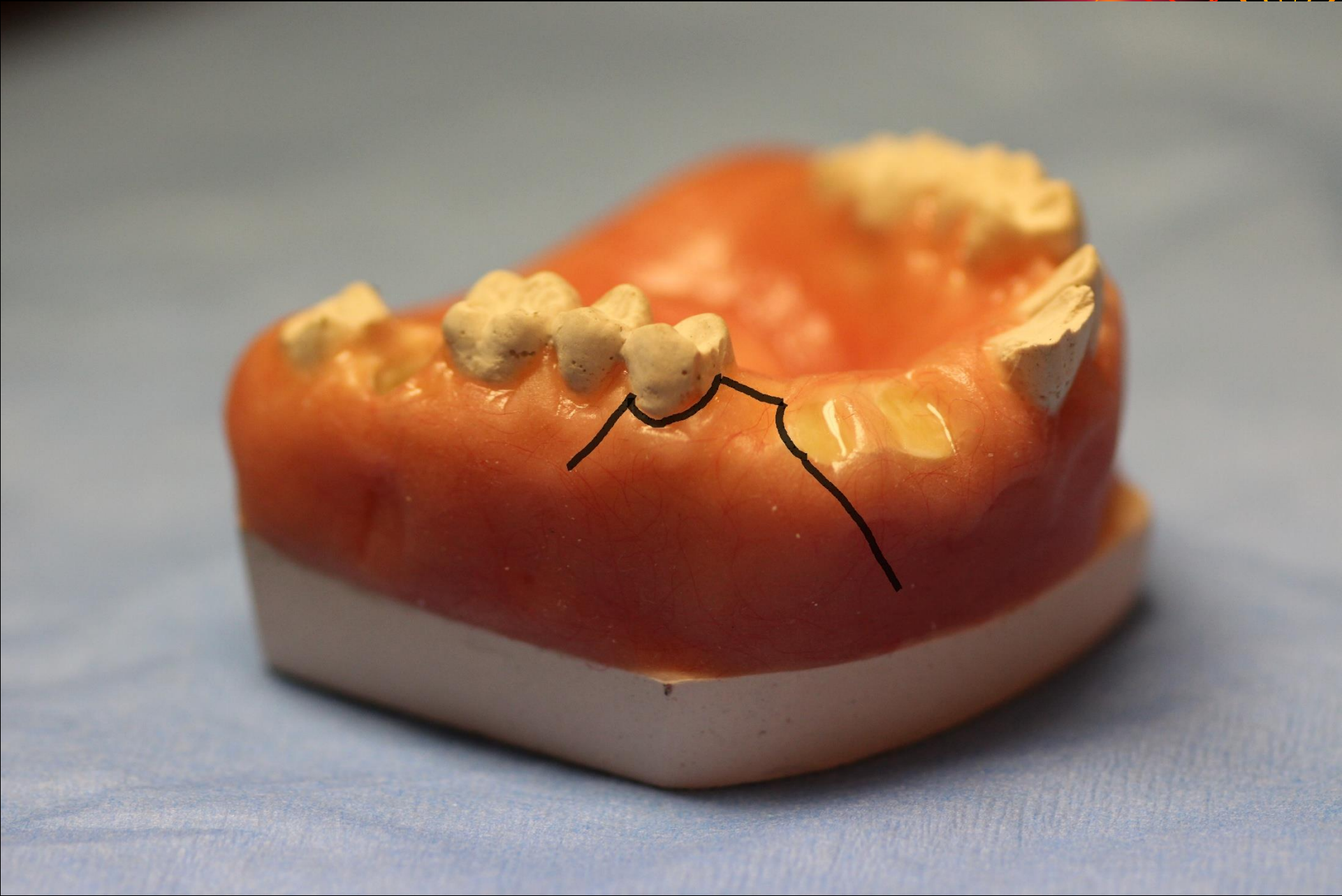

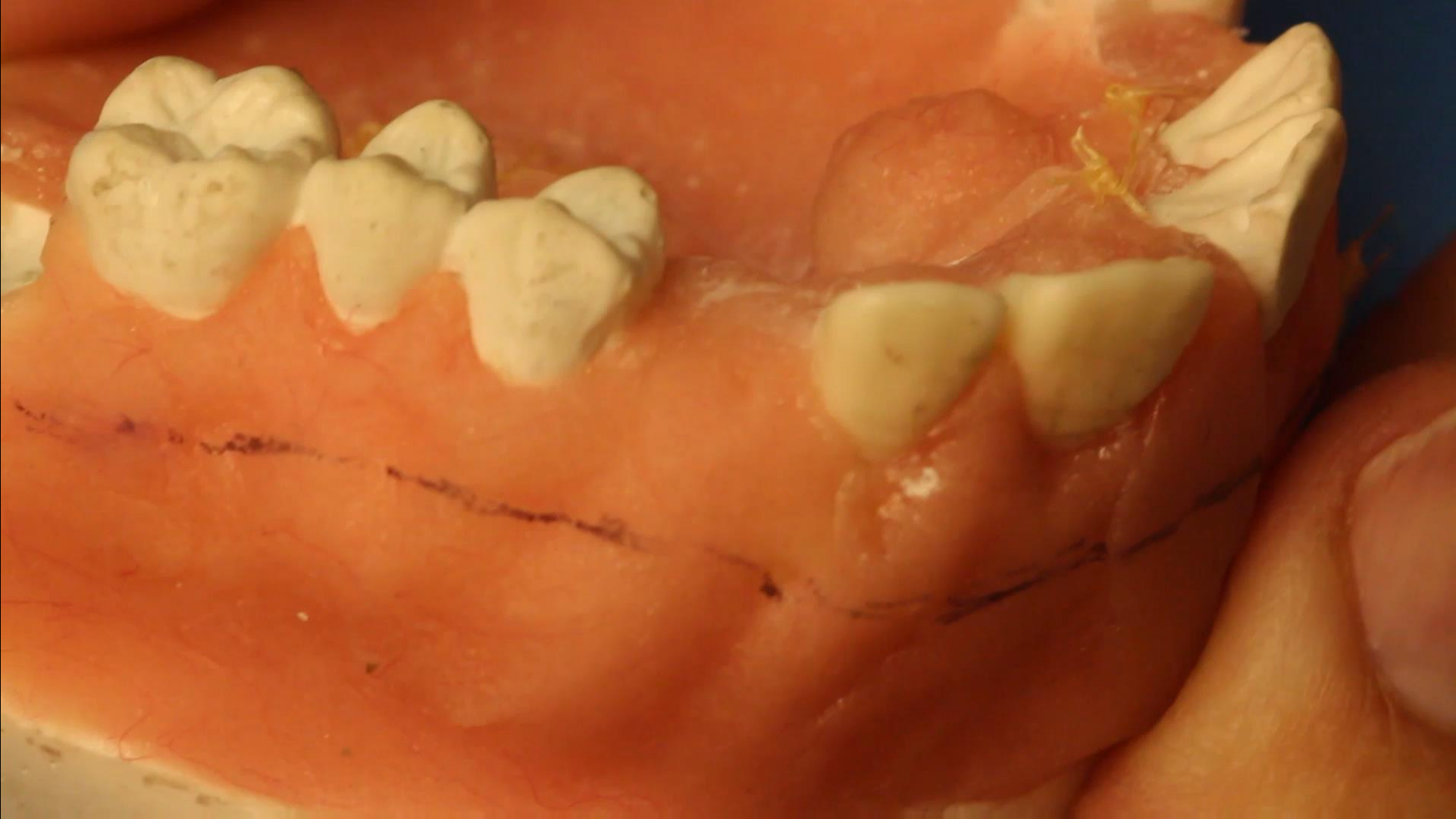

Soft tissue exposure tooth #6 apically repositioning flap

Complex Orthodontic Canine exposure #11 with gold bracket & chain

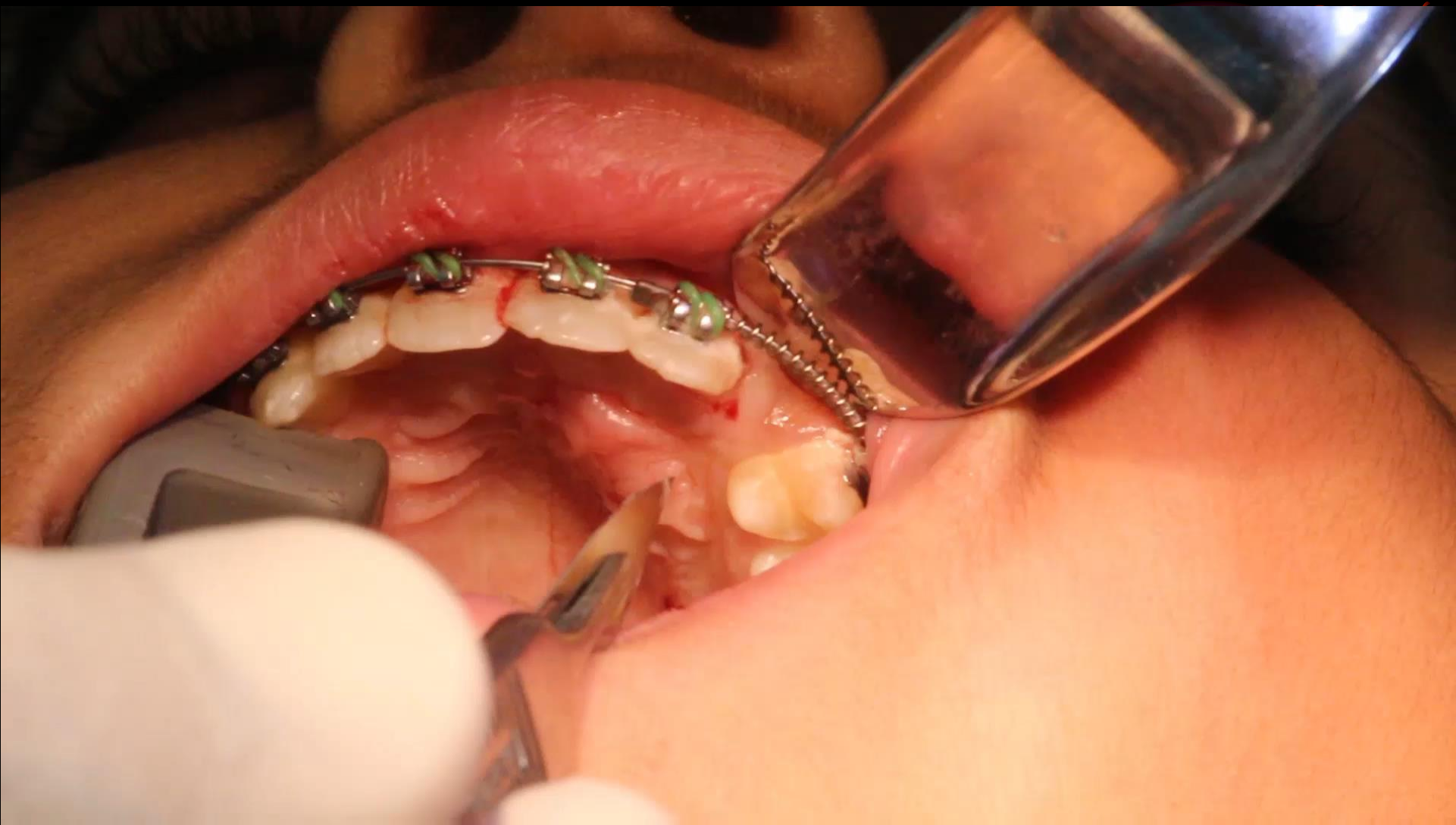
- **Flap design-usually Sulcular with release (buccal only)**
- **Preserve follicle at CEJ**
- **Avoid rotary instruments if possible, use elevators/osteotomes instead**
- **Remove bone to provide path for tooth, Avoid roots!**





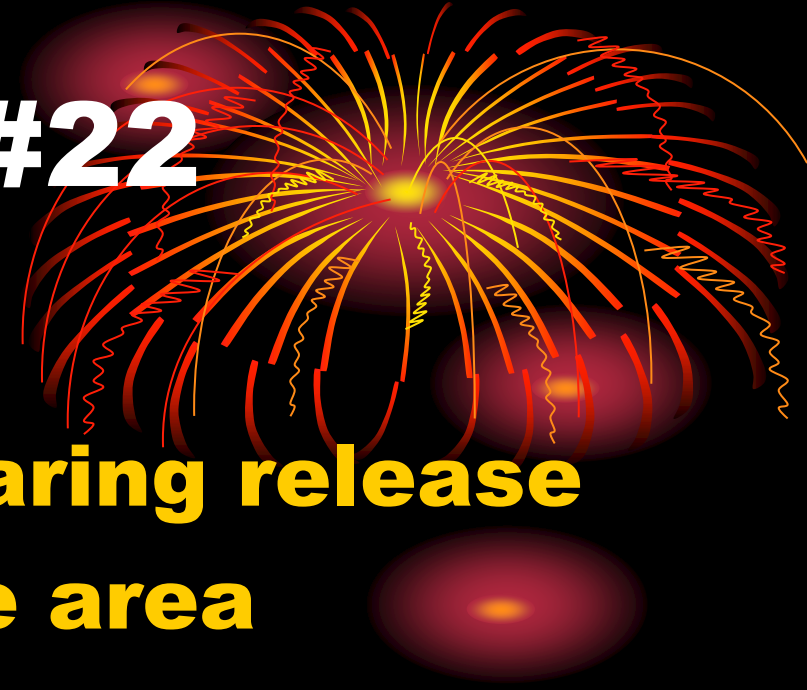

Complex Orthodontic exposure tooth #11 with bracket and chain

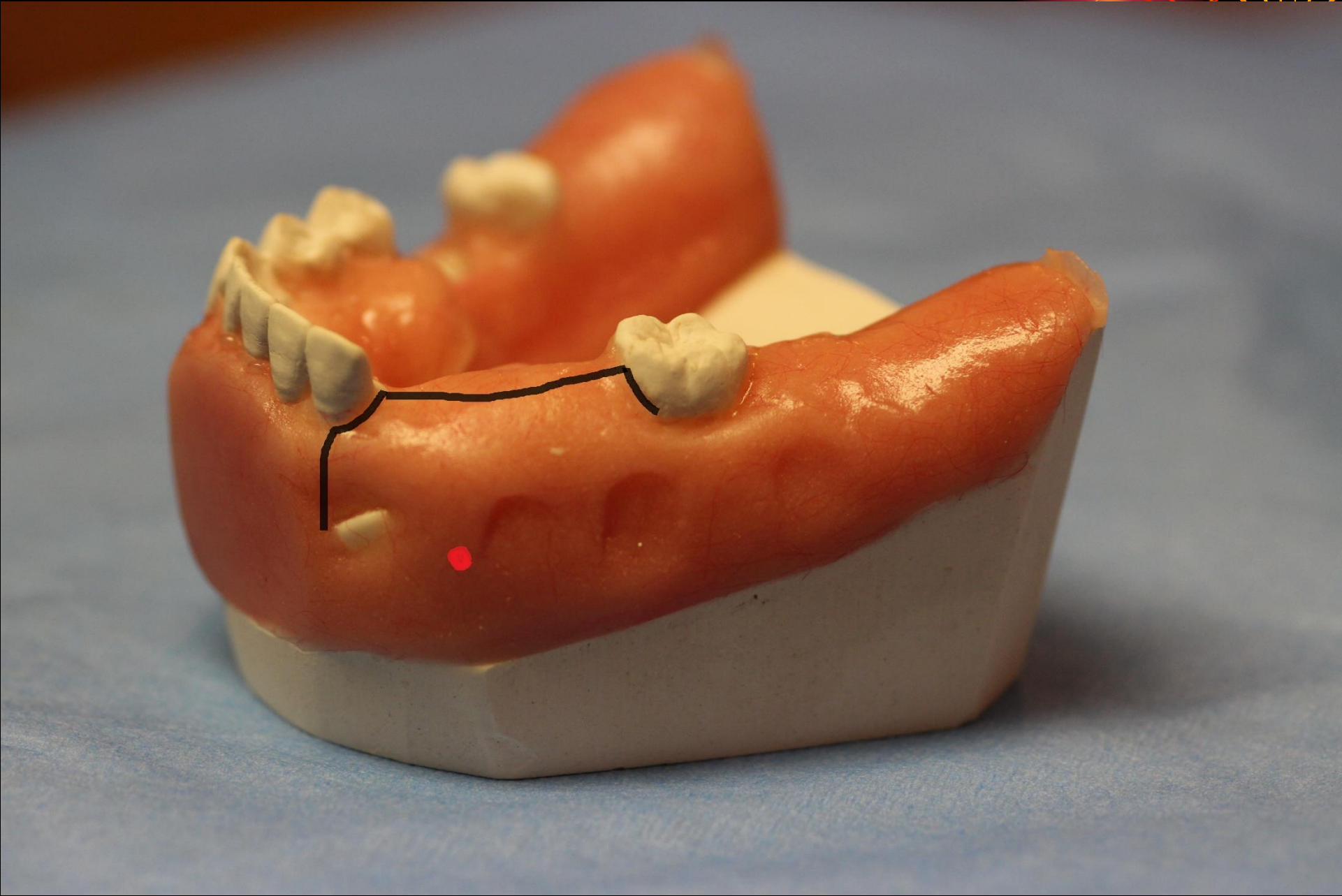


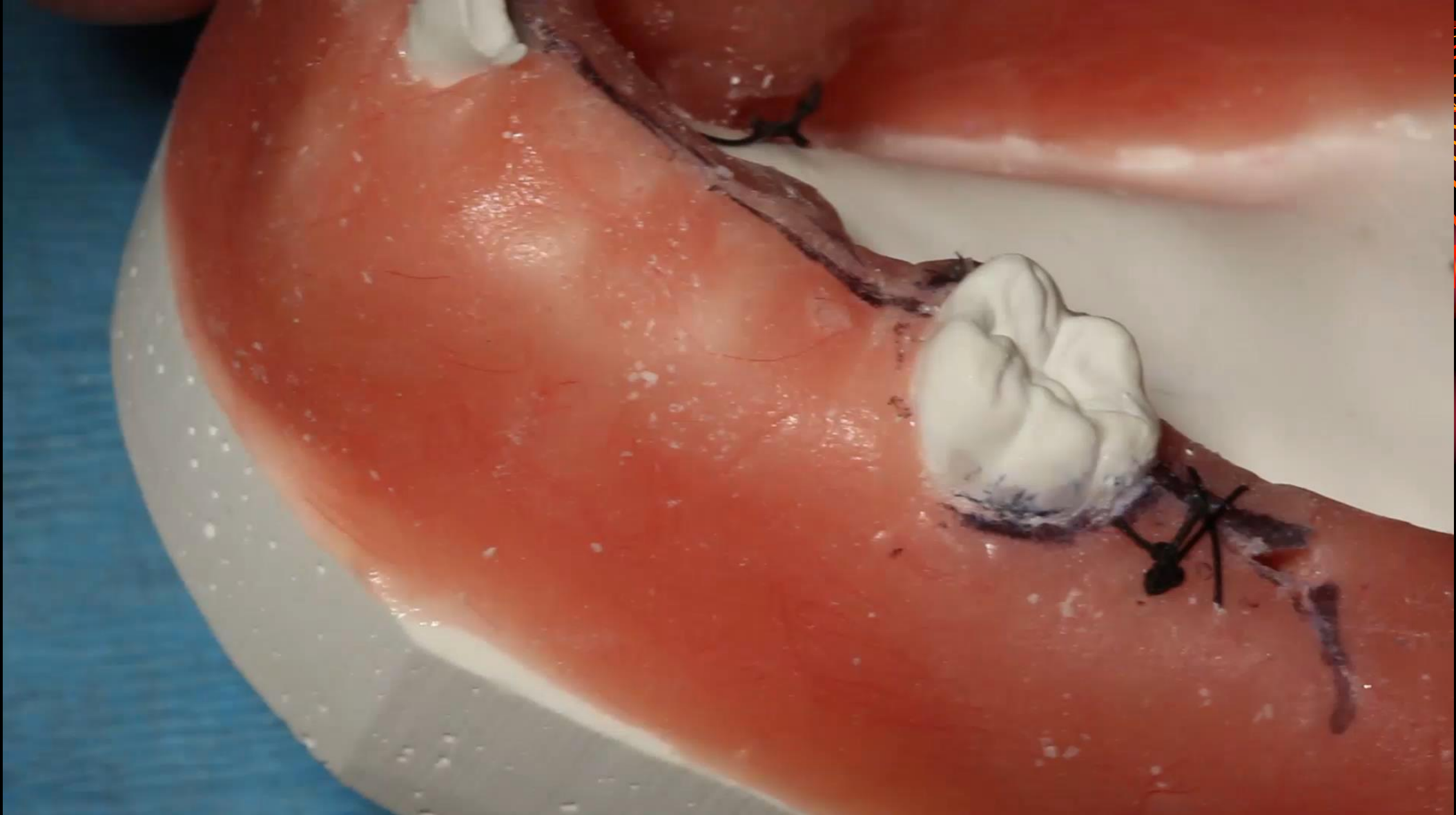
Complex Orthodontic exposure tooth with bracket and chain (Live)

Impacted canine #22 removal



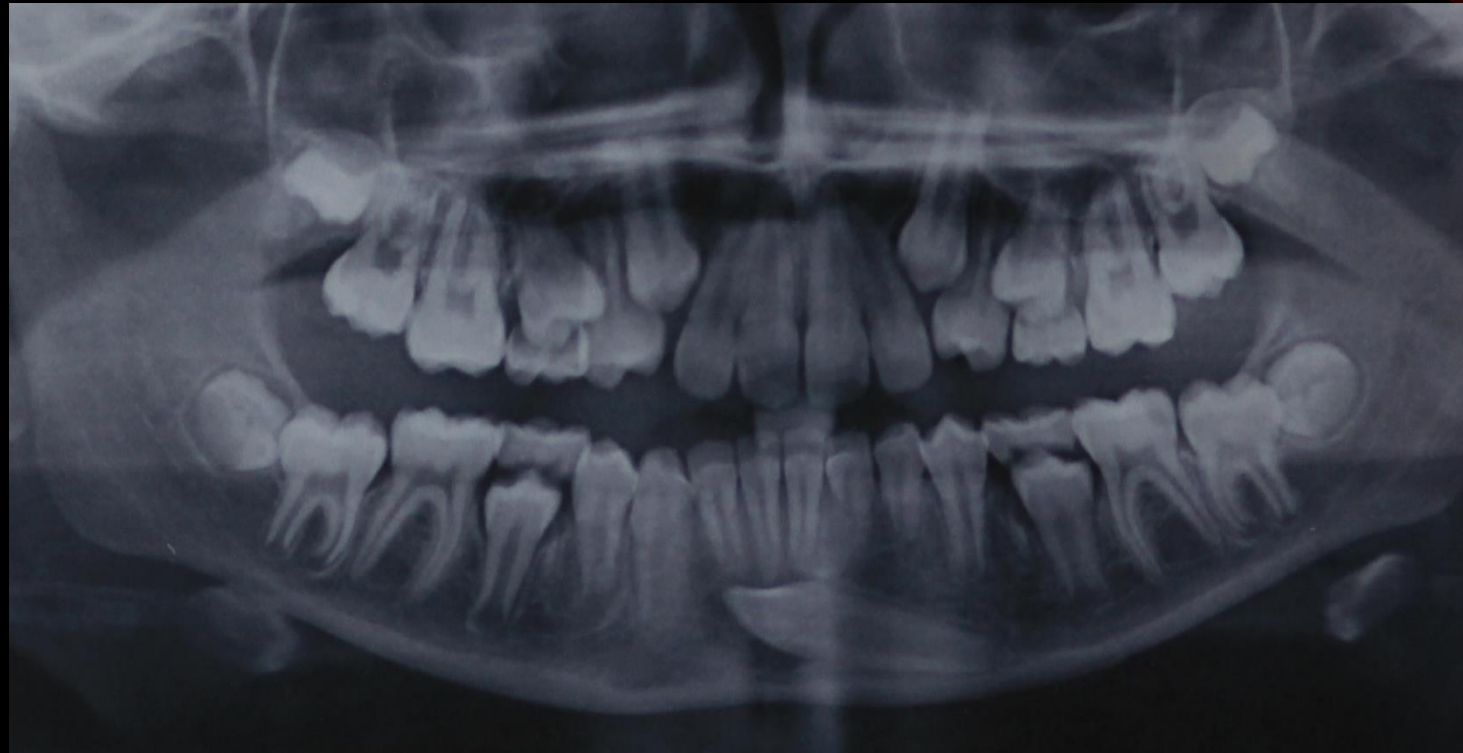
- **Crestal incision with papilla sparing release**
- **Avoid reflection in Mental nerve area**
- **Start elevation with Woodson**
- **Continuous locking suture closer**


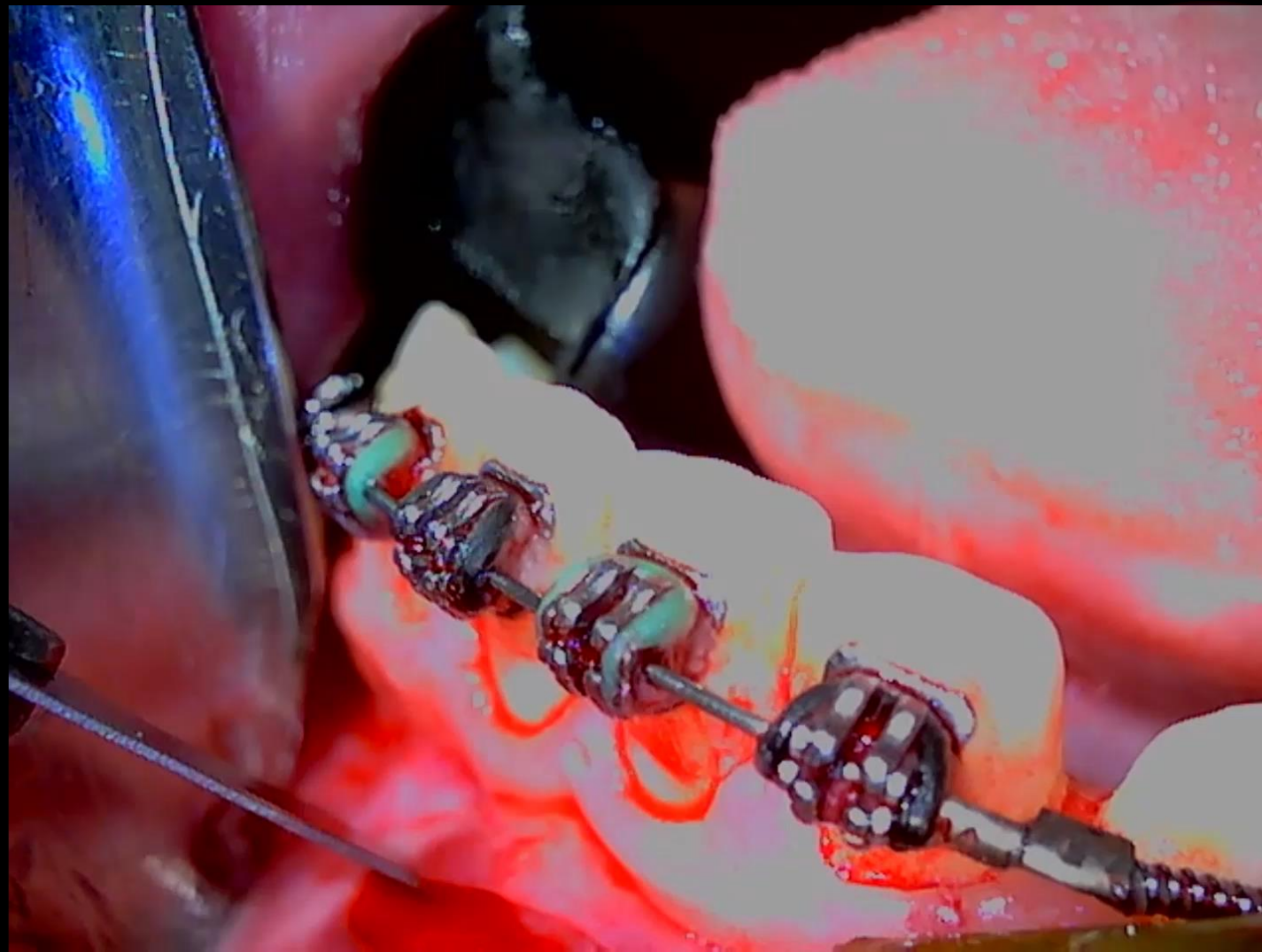




Removal of impacted canine #22 with continuous running suture

Canine removal/Ortho exposure without bracket (Transplant)



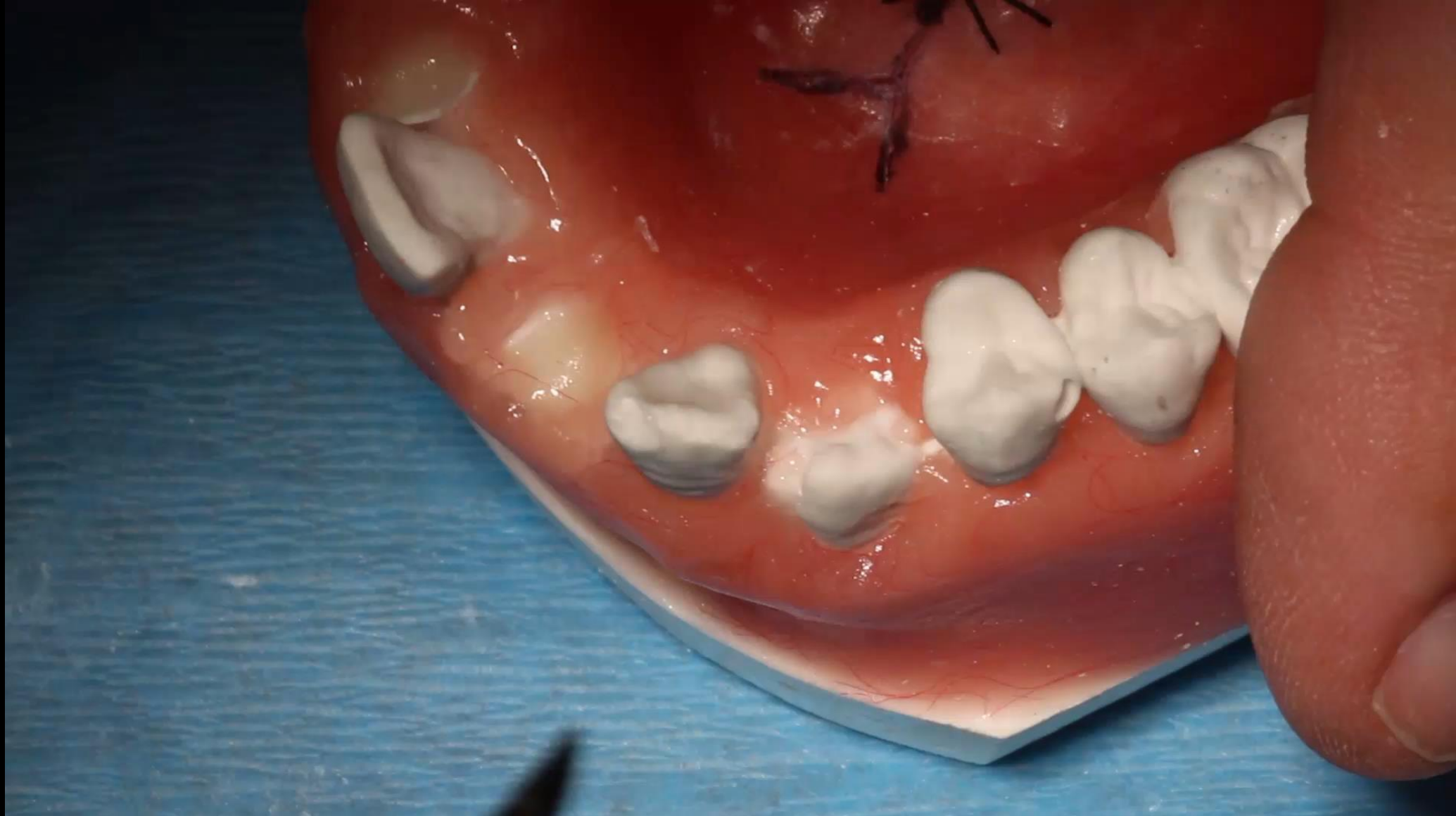



Ortho exposure without bracket (live)

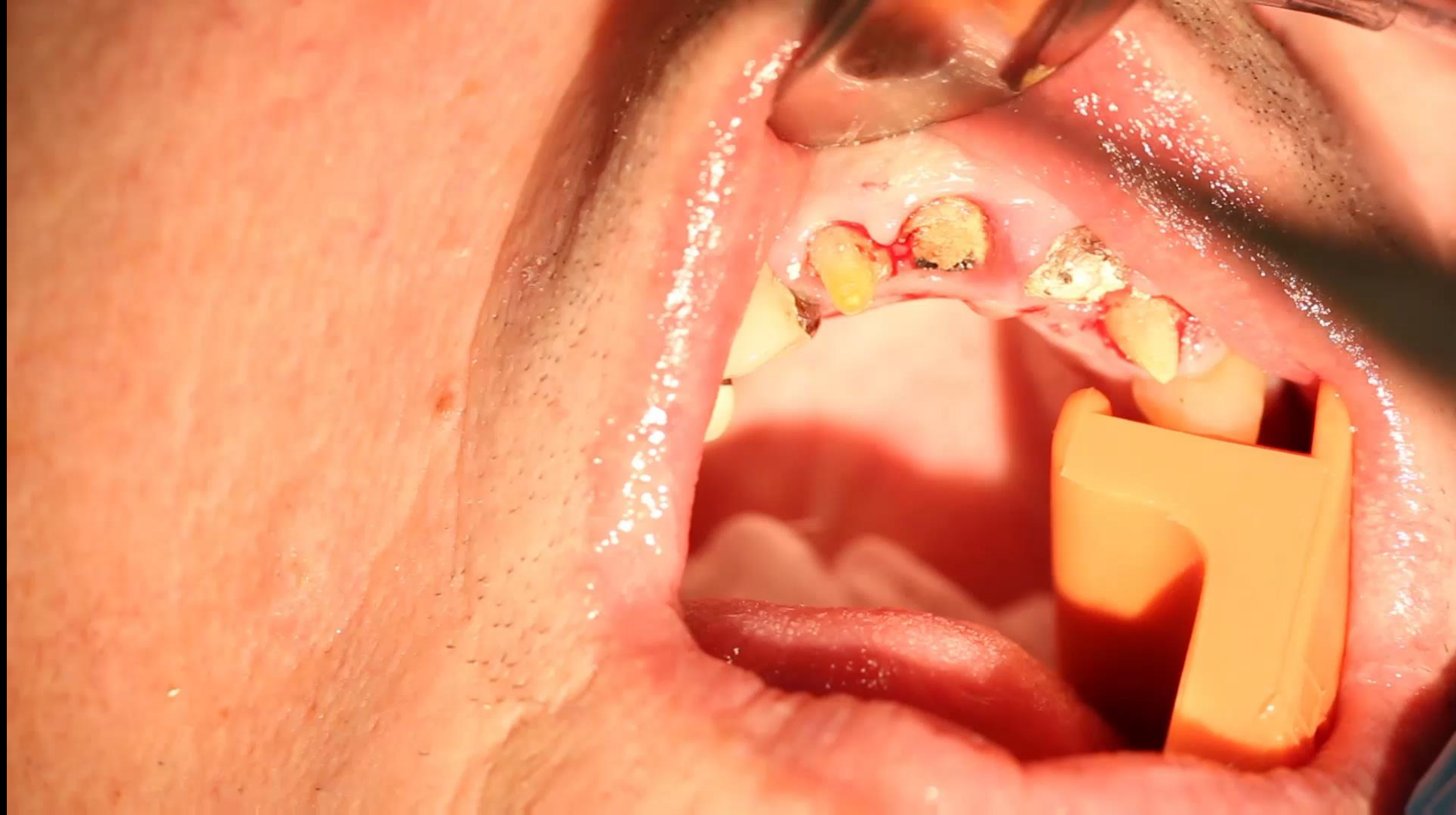
Residual roots #9 & #10 removal with osteotome

- **Incise down PDL with blade**
- **Work Woodson periosteal elevator or microtomes down PDL**
- **Start to apply more force working 360 degrees around root**
- **Start “tapping” osteotome**
- **Be Patient!!!! It will release**





Microtome removal of residual roots #8 & #10



Microtome removal of residual roots #9 & #10
(Live)


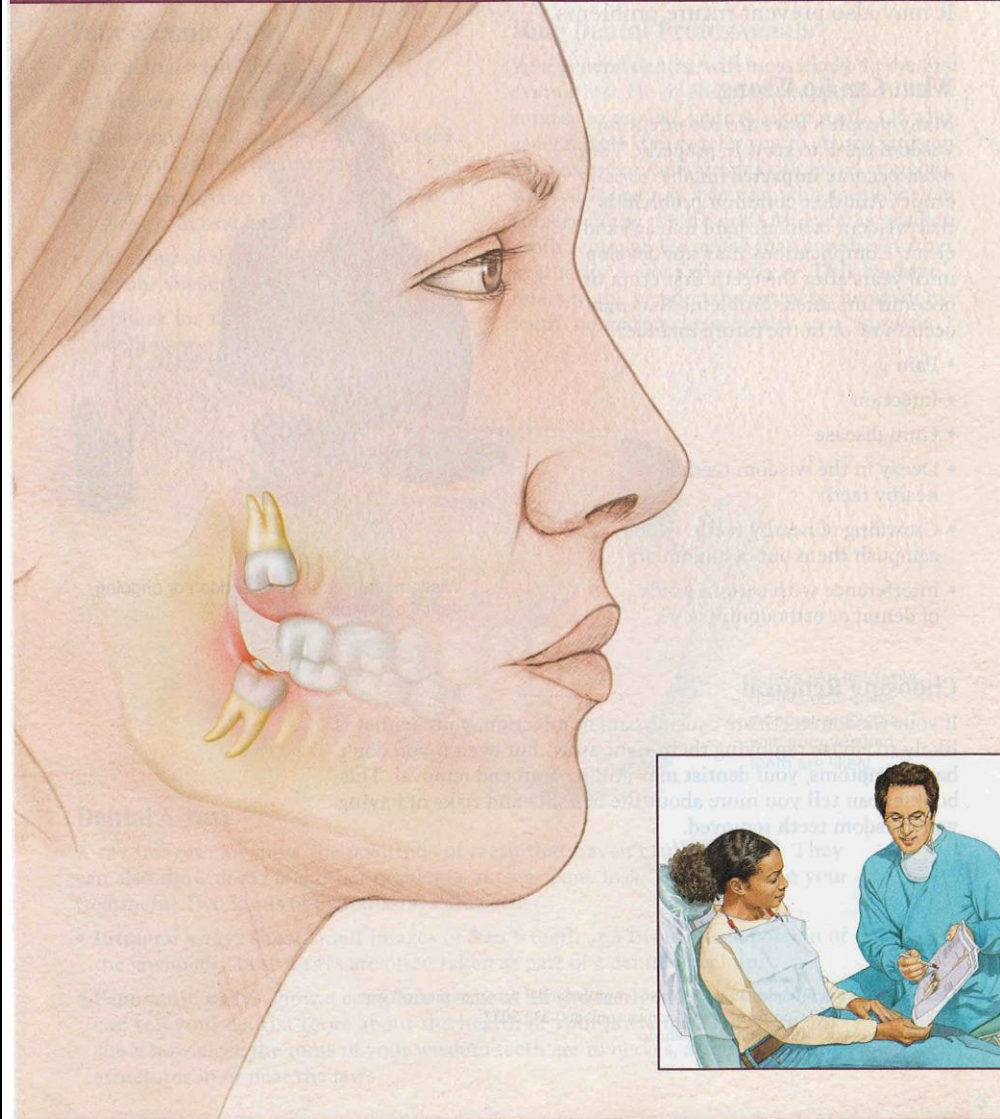
Consult and Consents

- **Recommend separate appointment**
- **Review x-rays & Clinical findings (order additional x-rays IE:--3D cone beam, labs, MD clearance, etc.)**
- **Patient/Parent views video consent (www.pbhs.com)**
- **Patient given handouts, written consent and Rx's**
- **Written Financial agreement with copayment and policies**




Wisdom Teeth Removal

Your Condition and Treatment






UNDERSTANDING

DENTAL IMPLANTS



Comfort
and
Confidence
Again



INFORMED CONSENT FOR IMPLANT SURGERY AND ANESTHESIA

This is my consent for Dr. Morris and/or any oral and maxillofacial surgeon who is working with him to perform the following treatment/procedure/surgery, as previously explained to me:

Special Instructions: _____

1. I have been informed and I understand the purpose and the nature of the implant surgery procedure. I understand what is necessary to accomplish the placement of the implant under the gum or in the bone.
2. My doctor has carefully examined my mouth. Alternatives to this treatment have been explained. I 'have tried or considered these methods, but I desire an implant to help secure the replaced missing teeth.
3. I have further been informed of the possible risks and complications involved with surgery, drugs, and anesthesia. Such complications include pain, swelling, infection and discoloration. Numbness of the lip, tongue, chin, cheek or teeth may occur. The exact duration may not be determinable and may be irreversible. Also possible are inflammation of a vein, injury of teeth present, bone fractures, sinus penetration, delayed healing, allergic reactions to drugs or medications used, etc.
4. I understand that if nothing is done, any of the following could occur: bone disease, loss of bone, gum tissue inflammation, infection, sensitivity, looseness of teeth, followed by necessity of extraction. Also possible are temporomandibular joint (law) problems, headaches, referred pains to the back of the neck and facial muscles, and tired muscles when chewing.
5. My doctor has explained that there is no method to accurately predict the gum and the bone healing capabilities in each patient following the placement of the implant.
6. It has been explained that in some instances implants fall and must be removed. I have been informed and understand that the practice of dentistry is not an exact science; no guarantees or assurance as to the outcome of results of treatment or surgery can be made.
7. I understand that excessive smoking, alcohol or sugar may effect gum healing and may limit the success of the implant. I agree to follow my doctor' 5 home care instructions. I agree to report to my doctor for regular examinations as instructed.
8. I agree to the type of anesthesia, depending on the choice of the doctor. I agree not to operate a motor vehicle or hazardous device for at least 24 hours or more until fully recovered from the effects of the anesthesia or drugs given for my care.
9. To my knowledge I have given an accurate report of my physical and mental health history. I have also reported any prior allergic or unusual reactions to drugs, food, insect bites, antibiotics, pollen dust, blood or body diseases, gum or skin reactions, abnormal bleeding or any other conditions related to my health.
10. I consent to photography, filming, recording and X-rays of the procedure to be performed for the advancement of implant dentistry, provided my identity is not revealed.
11. I request and authorize medical/dental services for me, including implants and other surgery. I fully understand that during and following the contemplated procedure, surgery or treatment, conditions may become apparent which warrant, in the judgement of the doctor, additional or alternative treatment pertinent tot he success of comprehensive treatment. I also approve any modification in design, materials or care, if it is felt this is for my best interest.

Signature of Doctor

Signature of Patient
(If the patient is unable to sign or is a minor,
signature of parent or legal guardian.)

Witness

Date



DOWNRIVER SURGERY CENTER

Under the laws of our state, it is our legal and ethical obligation to obtain written informed consent for any procedure contemplated. It is not our intention to scare or frighten you, but only to make you fully aware of the risks and benefits involved.*

INFORMED CONSENT FOR SURGERY AND ANESTHESIA

This is my consent for Dr. Morris and/or any oral and maxillofacial surgeon who is working with him to perform the following treatment/procedure/ surgery, as previously explained to me:

Special Instructions

*Patient is to initial each paragraph after reading.

_____ or other procedures deemed necessary or advisable to complete the planned operation.

I understand that the purpose of the treatment/procedure/surgery is to treat and possibly correct my diseased oral/maxillofacial tissues. The doctor has advised me that if this condition persists without treatment or surgery, my present oral condition will probably worsen in time; and the risks to my health may include, but not limited to, the following: swelling, pain, infection, cyst formation, periodontal (gum) diseases, dental caries, malocclusion, pathologic fracture of the jaw, premature loss of teeth, an/or premature loss of bone. I have been informed of possible alternative methods of treatment, if any.

_____ Dr. Morris has explained to me that there are certain inherent and potential risks in any treatment plan or procedure; and that in this specific instance, such operative risks include, but are not limited to: (Check applicable items.)

- _____ 1. Post-operative discomfort and swelling that may necessitate several days of home recuperation.
- _____ 2. Heavy bleeding that may be prolonged.
- _____ 3. Injury to adjacent teeth and fillings.
- _____ 4. Post-operative infection requiring additional treatment; dry sockets.
- _____ 5. Stretching of the corners of the mouth with resultant cracking and bruising.
- _____ 6. Restricted mouth opening for several days or weeks.
- _____ 7. Decision to leave a small piece of root in the jaw when its removal would require extensive surgery.
- _____ 8. Breakage of the jaw.
- _____ 9. Injury to the nerve underlying the teeth, resulting in numbness or tingling of the lip, chin, gums, cheek, teeth and/or tongue on operated side. This may persist for several weeks, months or, in remote instances, permanently.
- _____ 10. Opening of the sinus (a normal cavity situated above the upper teeth), requiring additional surgery.
- _____ 11. Other.

_____ I understand that I am not to have anything to eat or drink for six (6) hours before my surgery if having general anesthesia and that I will bring a responsible adult to stay here and drive me home.

_____ I consent to administration of such local and/or general anesthesia as deemed necessary by Dr. Morris and/or his designated assistants to accomplish the proposed procedure.

_____ Medications, drugs, anesthetics and prescriptions may cause drowsiness and lack of awareness and coordination, which can be increased by the use of alcohol or other drugs; thus, I have been advised not to operate any vehicle or hazardous device, or to work, while taking such medications and/or drugs, or until fully recovered from the effects of the same. I agree not to operate any vehicle or hazardous device for a least twenty-four (24) hours after my release from surgery or until further recovered from the effects of the anesthetics, medications and drugs that may have been given to me in the office or hospital. I agree not to drive after surgery and will have a responsible adult drive me or accompany me home after my discharge from surgery.

_____ I understand that certain anesthetic risks, which could involve serious bodily injury, are inherent in any procedure that requires a general anesthetic.

_____ If any unforeseen condition should arise in the course of the operation, calling for the doctor's judgement or for procedures in addition to or different from those now contemplated, I request and authorize the doctor to do whatever he may deem advisable.

_____ No guarantee or assurance has been given to me that the proposed treatment will be curative and/or successful to my complete satisfaction. Due to individual patient differences, there exists a risk of failure, relapse, selective retreatment, or worsening of my present condition, despite the care provided. However, it is the doctor's opinion that therapy would be helpful, and that a worsening of my condition would occur sooner without the recommended treatment.

_____ I have had an opportunity to discuss with Dr. Morris my past medical and health history, including any serious problems and/or injuries.

_____ I agree to cooperate completely with the recommendations of Dr. Morris while I am under his care, realizing that any lack of same could result in a less than optimum result.

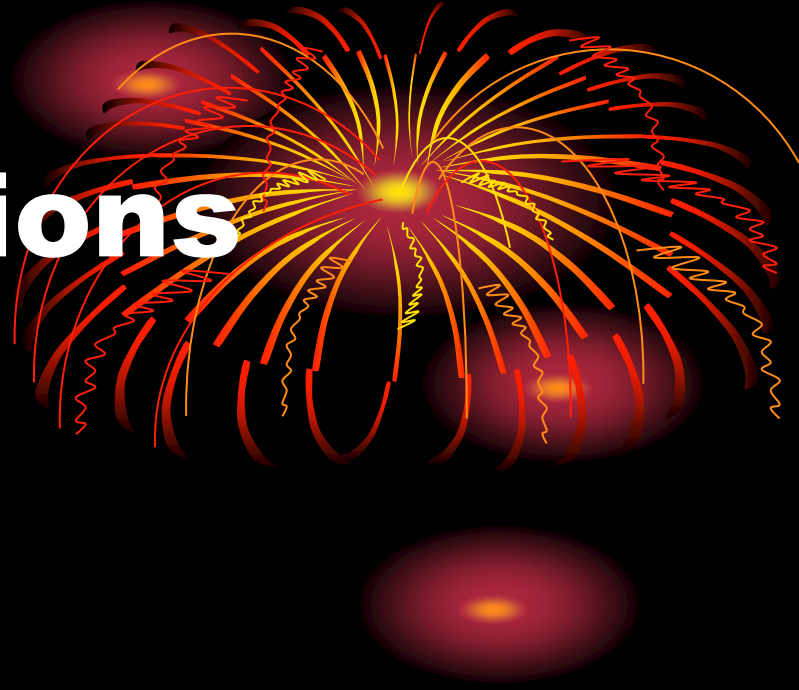I CERTIFY THAT I HAVE READ AND FULLY UNDERSTAND THE TERMS, WORDS AND EXPLANATIONS REFERRED TO OR MADE IN THE ABOVE TO THE OPERATION; THAT ALL BLANKS OR STATEMENTS REQUIRING INSERTION OR COMPLETION WERE FILLED IN; AND THAT INAPPLICABLE PARAGRAPHS, IF ANY, WERE STRICKEN BEFORE I SIGNED. I ALSO CERTIFY THAT I READ AND WRITE ENGLISH.

Witness _____ Patient, Parent or Guardian _____ Date _____

Witness _____ Doctor _____ Date _____




Treatment of Complications



- **Bleeding**
- **Dry Sockets**
- **Infections**
- **Paresthesia**
- **Nausea and Vomiting**
- **Allergic or drug side effects**
- **MRONJ (BRONJ) – Medicated Related Osteonecrosis of the Jaw**

Causes of bleeding

- **Anticoagulants:**
 - **Warfarin (Coumadin)**
 - **Aspirin**
 - **Clopidogrel(Plavix)**
 - **Dabigatran(Pradaxa)**
 - **Enoxaparin(Lovenox)**
 - **Herbal Supplements & Fish Oils**
- **High blood pressure**
- **Hemophilia's genetic/acquired**



Drugs that can cause bleeding

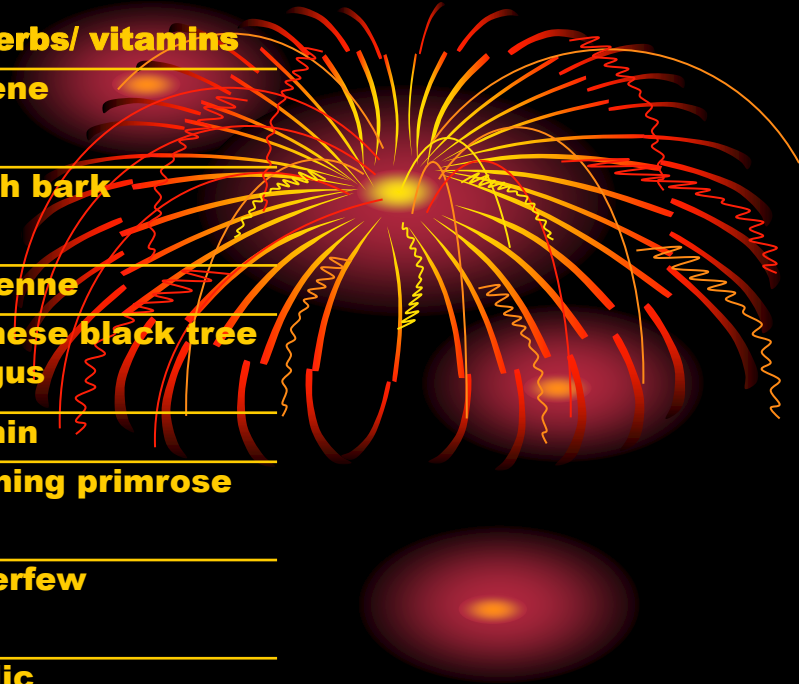
Aceclofenac
Acenocoumarol
Acetylsalicylic
acid (Aspirin)
Citalopram*
Clopidogrel
Dexibrufen
Diclofenac
Dicoumarol
Escitalopram
Fluoxetine*
Fluvoxamine*
Ibuprofen
Indomethacin
Ketoprofen

Ketorolac
Lornoxicam
Meloxicam
Nabumetone
Naproxen
Paroxetine*
Phenprocoum
on
Piroxicam
Sertraline*
Sulindac
Tenoxicam
Ticlopidine
Warfarin




Drugs that make you bleed!

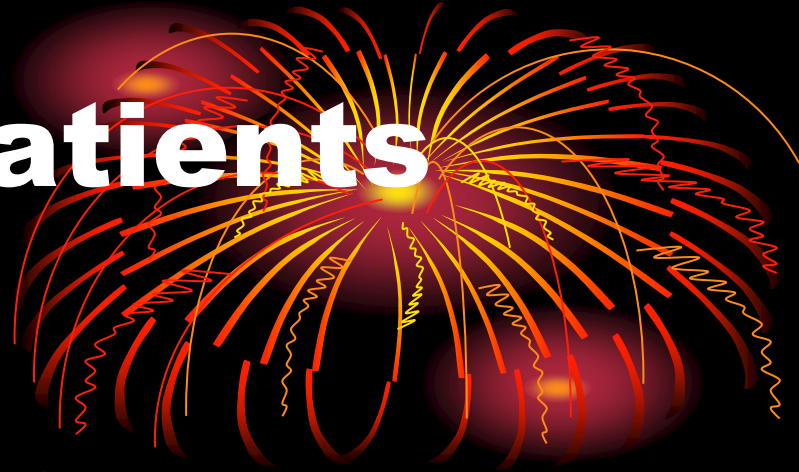Non-steroidal anti-inflammatory drugs		Herbs/ vitamins
Diclofenac (Voltaren[®], Cataflam[®])	Tolmetin (Tolectin[®])	Ajoene
Diflunisal (Dolobid[®])	Trilisate (Salicylate combination)	Birch bark
Etodolac (Lodine[®])		Cayenne
Fenoprofen (Nalfon[®])		Chinese black tree fungus
Flurbiprofen (Ansaid[®])		Cumin
Ibuprofen (Motrin[®], Advil[®], Nuprin[®], Rufen[®])		Evening primrose oil
Indomethacin (Indocin[®])		Feverfew
Ketoprofen (Orudis[®], Actron[®])		Garlic
Ketorolac (Toradol[®])		Ginger
Meclofenamate (Meclomen[®])		Ginkgo biloba
Meloxicam (Mobic[®])		Ginseng
Nabumeton (Relafen[®])		Grapeseed extract
Naproxen (Naprosyn[®], Naprelan[®], Aleve[®])		Milk thistle
Oxaprozin (Daypro[®])		Omega 3 fatty acids
Piroxicam (Feldene[®])		Onion extract
Salsalate (Salflex[®], Disalcid[®])		St. John's wort
Sulindac (Clinoril[®])		Tumeric
Sulfinpyrazone		Vitamins C & E



Condition	<u>Prothrombin time</u>	<u>Partial thromboplastin time</u>	Bleeding time	<u>Platelet count</u>
<u>Vitamin K deficiency or warfarin</u>	Prolonged	Normal or mildly prolonged	Unaffected	Unaffected
<u>Disseminated intravascular coagulation</u>	Prolonged	Prolonged	Prolonged	Decreased
<u>Von Willebrand disease</u>	Unaffected	Prolonged	Prolonged	Unaffected
<u>Hemophilia</u>	Unaffected	Prolonged	Unaffected	Unaffected
<u>Aspirin</u>	Unaffected	Unaffected	Prolonged	Unaffected
<u>Thrombocytopenia</u>	Unaffected	Unaffected	Prolonged	Decreased
<u>Liver failure, early</u>	Prolonged	Unaffected	Unaffected	Unaffected
<u>Liver failure, end-stage</u>	Prolonged	Prolonged	Prolonged	Decreased
<u>Uremia</u>	Unaffected	Unaffected	Prolonged	Unaffected
<u>Congenital afibrinogenemia</u>	Prolonged	Prolonged	Prolonged	Unaffected
<u>Factor V deficiency</u>	Prolonged	Prolonged	Unaffected	Unaffected
<u>Factor X deficiency as seen in amyloid purpura</u>	Prolonged	Prolonged	Unaffected	Unaffected
<u>Glanzmann's thrombasthenia</u>	Unaffected	Unaffected	Prolonged	Unaffected
<u>Bernard-Soulier syndrome</u>	Unaffected	Unaffected	Prolonged	Decreased or unaffected
<u>Factor XII deficiency</u>	Unaffected	Prolonged	Unaffected	Unaffected



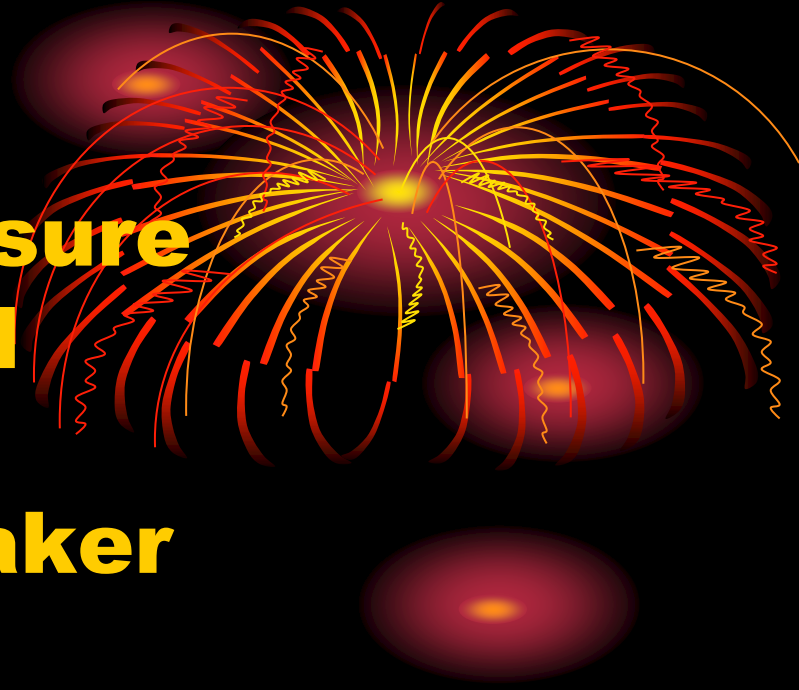Recommendations for Patients on Anticoagulants




- **Do not stop anticoagulant (as a general rule)**
- **Check INR ≤ 3 and/or bleeding time ≤ 5 minutes**
- **Minimize surgery/stage procedures**
- **Remove all granulation tissue**
- **“Socket Preservation” with gel foam block/membrane, suture and tissue glue seal**

Bleeding!

- **Intraoperative control-pressure packs, hemostat clamp and suture or electro-cautery (contraindicated in Pacemaker patients)**
- **Laser**
- **Vitamin “S” (suture it closed!)**
- **Silver Nitrate cautery sticks**
- **Bone wax (questionable value in oral sockets)**
- **Adjunct clotting materials**



Adjunct Materials for **Bleeding!**




- **Collagen foam, plugs, gauze & tape**
- **Regenerated Cellulose- Blood Block HemoGauze**
- **Chitosan impregnated gauze- HemCon ChitoGauze**
- **Block graft material (Bio-Os)**
- **Tissue glue- PeriAcryl 90 (www.glustitch.com)**
- **Topical Thrombin (bovine) and new human Evithrom (www.ethicon360.com)**
- **Tranexamic acid-IV or Oral preop**
- **Aminocaproic acid- Amicar IV or oral preop**
- **Avitene Powder-microfibrillar collagen**
- **Fibrin glues/sealants- www.tisseel.com**
- **PRP-plasma rich platelet concentrate**
- **Vitamin K injections and Fresh Frozen Plasma**
- **Warm Tea Bag-wring out and apply**

Dry Sockets!!!!

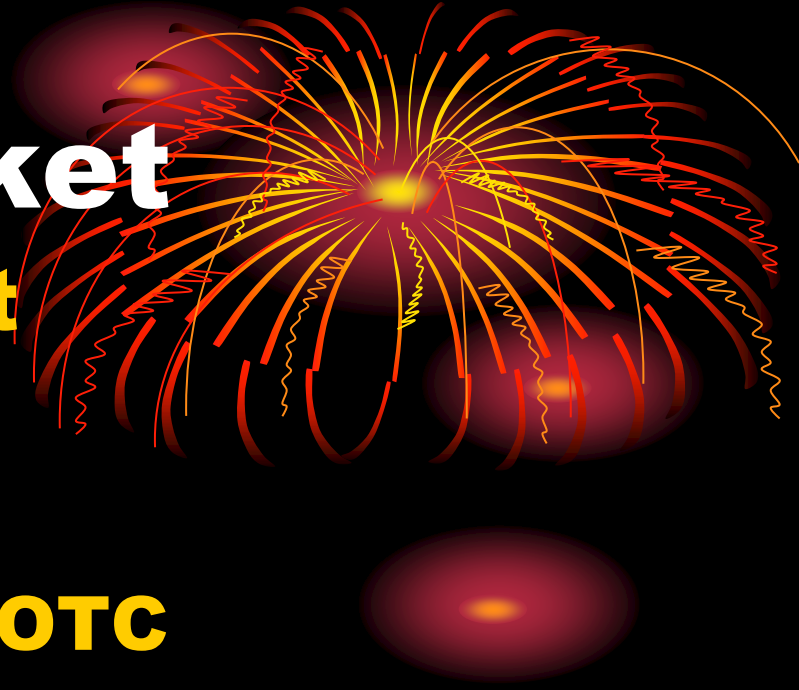
(Fibrolytic Alveolitis)

- **National incidence 15-25%**
(depending on experience)
- **Usually 3-5 days for onset**
- **Almost exclusively in Mandible**
- **Risk factors-Smoking, infection, birth control pills/injections, estrogen supplements, Diabetes, Immunocompromised**
- **Poor sterile and surgical technique**
- **Sucking on Straws Have Nothing to do with it !!!!!!!!!!!!!!!!!!!!!!!!!!!!!!!**



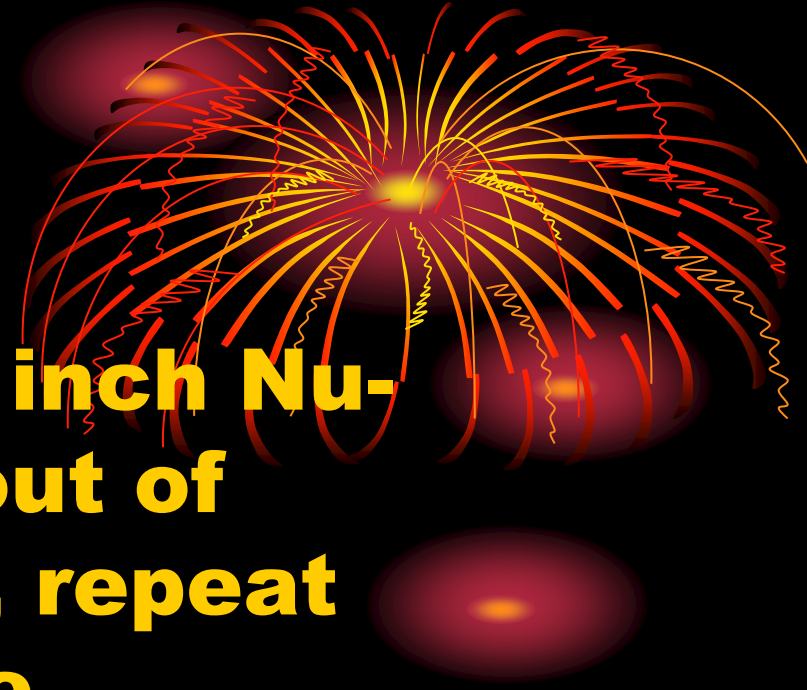Treatment of Dry Socket

- Irrigate in the office and at home with mixture of:
 - 6 oz of warm salt water
 - 1 oz hydrogen peroxide 3% OTC
 - 1 oz mouthwash (peridex, Listerine, Aquafresh, etc.)
- Make sure patient has irrigating syringe and instruct them on how to use it!
- Take X-ray and check for tooth/root/bone fragments



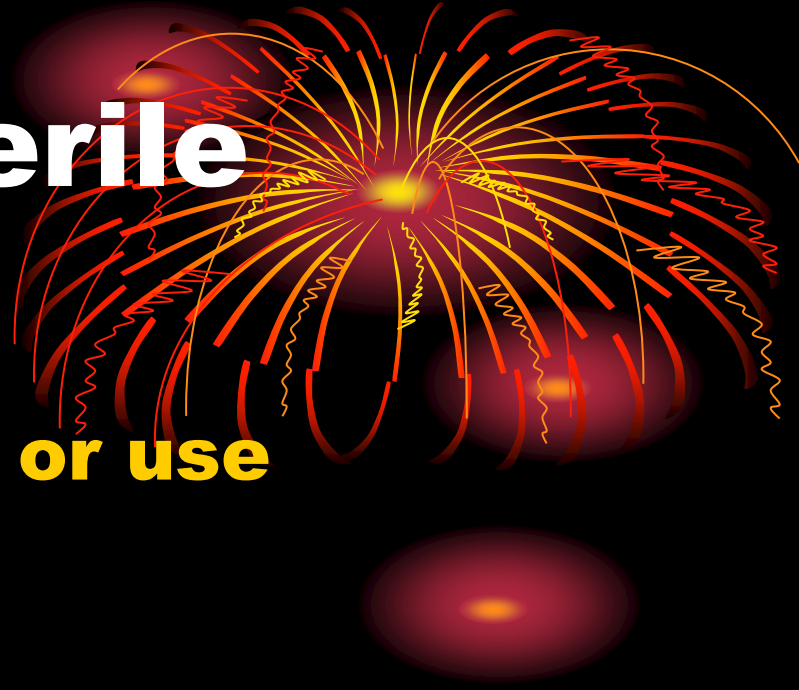
Dry Socket

- **Gently pack socket with ¼ inch Nu-gauze (gel foam if leaving out of town) soaked in Dentalone, repeat daily for 2-3 days if possible**
- **Apply topical after irrigating socket and you can mix some topical in with Dentalone if needed**
- **Start Antibiotic or change to AB that covers Gram Neg bacteria, such as Clindamycin**





Recommendation for Sterile Technique


- **Autoclave everything possible or use disposables**
- **Use a sterile water supply**
- **Use Nitrogen or electric powered drills**
- **Gas (Ethylene oxide) plastic high volume suction hoses and water/air syringes or Sterile sleeves**
- **Use Sterile gloves**
- **Practice sterile technique!**



Aseptico Tank



Handpiece Connections





Anderson Gas Sterilizer




Infections

- **Prevention is the best medicine**
- **For routine procedures ASA 1 and no risk factors, and no drilling!**
 - **Keflex 250 mg QID for 5 days**
 - **Keflex 500 mg QID (750mg BID) for 10 days if infection or drilling involved**
 - **Try to give 1 Gm 1 hour pre-operatively!**
 - **Clindamycin, Z-Pak, Augmentin, Cipro as alternatives**



Paresthesia's

- **Generally only in the Mandibular division of the Trigeminal nerve**
- **Most often secondary to swelling from local trauma either induced by “sawing” the needle with repeated injections**
- **Use of Septocaine 4%**
- **Hematomas**
- **Direct trauma from removal of the roots**
- **Poor design of flap**



Evaluation of Parathesia



- **Classification of injury and document it**
- **Neuropraxia---non Wallerian degeneration,
nerve intact, and general partial loss,
Sensation intact but diminished**

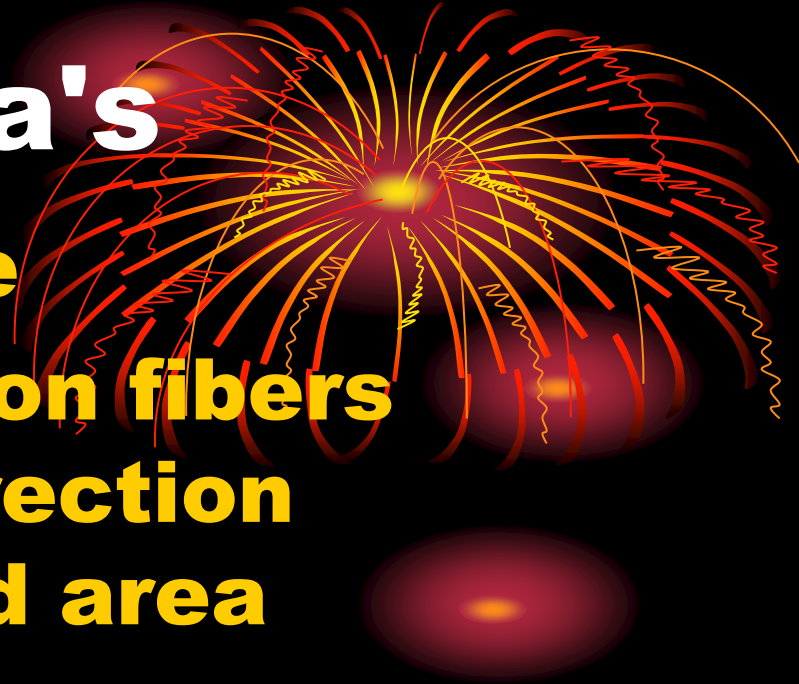Classification of Nerve Injuries

Types of Nerve Injury

- **Neuropraxia:** physiologic block of nerve (swelling), usually recover spontaneously when swelling is gone 3-12 weeks
Partial numbness and gradual improvement weekly
- **Axonotmesis:** anatomic disruption of axon with little disruption of connective tissue, nerve intact, usually almost complete
Numbness, spontaneous return in 6-12 months
- **Neurotmesis:** anatomic disruption of axon and connective tissue, complete numbness over entire distribution, low probability of spontaneous return in 9-12 months


Testing of Paresthesia's

- **Test against the normal side**
- **Light brush stroke with cotton fibers (Q-Tip pulled apart), note direction and perception of innervated area**
- **Pin prick- map area of perception and % of loss**
- **2-point discrimination with cotton plier I.E.—closed, 1mm, 3mm, 5mm and wide open**
- **When in doubt, early referral for evaluation**



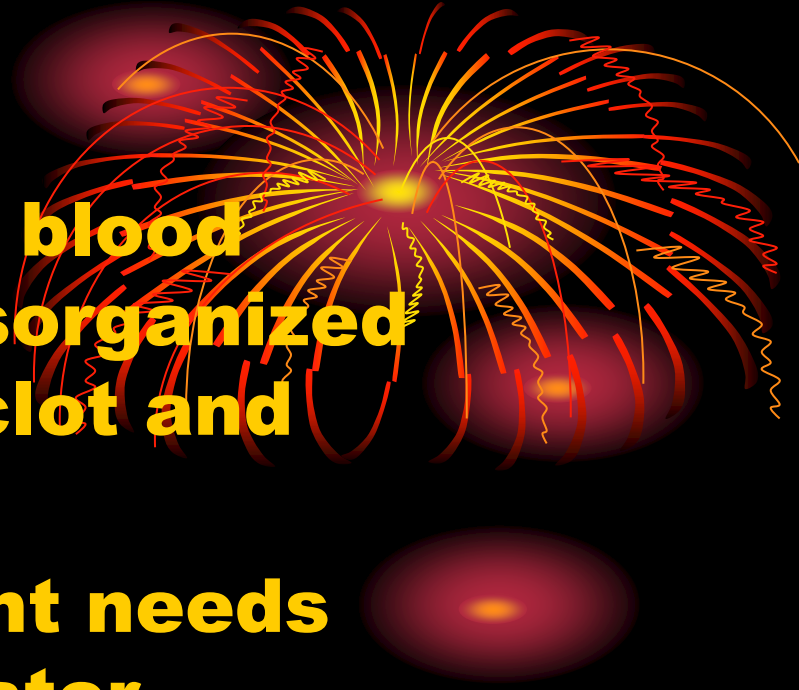Steroid Use

- **Generally for most surgeries, except severe infections**
- **Decadron (Dexamethasone) 4-8mg (1-2cc) injection into the “anesthetized” surgical site (burns terribly) can be given IV**
- **Also helps with Nausea, vomiting, asthma, and arousing sedated patients**



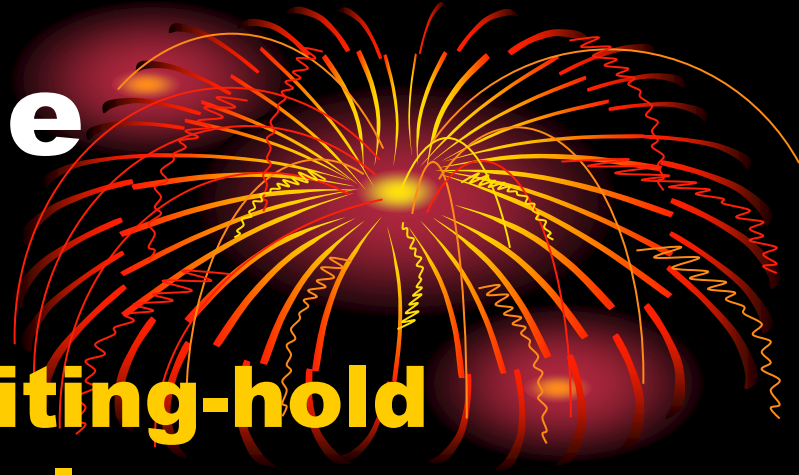Nausea and Vomiting

- **Post op usually from swallowing blood secondary to bleeding from a disorganized blood clot, (Liver Clot) Remove clot and apply pressure with fresh gauze**
- **Secondary to medications-Patient needs to try to eat and drink a lot of water behind Meds**
- **Small sips of flat (shake the carbonation out) Coke or ginger-ale**
- **Liquid Children's Benadryl 25-50mg**
- **Dramamine/Bonine Chewable tablets**
- **RX-suppositories Compazine/Phenergan**



Allergic or Drug Side Effects

- **Most common- Nausea/Vomiting-hold drugs and follow N/V protocol**
- **Rash/Itching-mild, use Benadryl OTC**
 - **Moderate to severe reaction--RX Medrol Dose-Pak, Change Rx's**
 - **In office rare-Decadron 8mg IM followed by Medrol Dose-Pak or Epinephrine for Anaphylaxis**




MRONJ – Medicated (Bisphosphonate) Related (Anti-Resorptive) Osteonecrosis of the Jaw (not BRONJ)

- **Risks very low with Oral Dosing**
 - **Less than 1/2%**
 - **Up to 10% with IV therapy (usually getting Chemotherapy and/or Radiation)**
- **Pre and Post antibiotic therapy**
- **“Rough up” or perforate socket walls to encourage bleeding**
- **Recommended “drug holiday” for 3 months**
- **Can be treated early and locally with good success with Saucerization and Sequestrectomy**



MRONJ-Medicated Related Osteonecrosis of the Jaw



- **Denosumab is a human monoclonal antibody for the treatment of osteoporosis**
- **Trade names Xgeva and Prolia, newest addition is Evenity (Romosozumab-aqqg)**

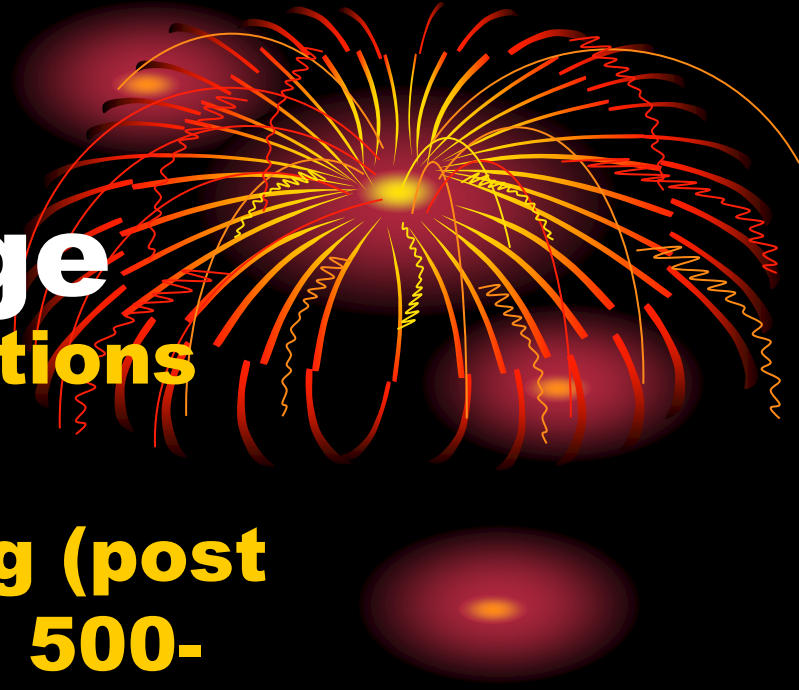Bisphosphonates-

Class	Name	R ¹	R ²	Relative potency (vs Etidronate=1)
Non-nitrogenous	<u>Etidronate</u> (Didronel)	OH	CH ₃	1
	<u>Clodronate</u> (Bonefos, Loron)	Cl	Cl	10
	<u>Tiludronate</u> (Skelid)	H	<i>p</i> -Chlorophenylthio	10
Nitrogenous	<u>Pamidronate</u> (APD, Aredia)	OH	(CH ₂) ₂ NH ₂	100
	<u>Neridronate</u> (Nerixia ^[39])	OH	(CH ₂) ₅ NH ₂	100
	<u>Olpadronate</u>	OH	(CH ₂) ₂ N(CH ₃) ₂	500
	<u>Alendronate</u> (Fosamax)	OH	(CH ₂) ₃ NH ₂	500
	<u>Ibandronate</u> (Boniva - US, Bonviva - Asia)	OH	(CH ₂) ₂ N(CH ₃)(CH ₂) ₄ CH ₃	1000
	<u>Risedronate</u> (Actonel)	OH	3-Pyridylmethyl	2000
	<u>Zoledronate</u> (Zometa, Aclasta)	OH	1 <i>H</i> -imidazol-1-ylmethyl	10000



Post operative Instructions/Discharge

- **Give verbal and written instructions (document)**
- **Pre operative Motrin 400-800mg (post operative if IV General) Tylenol 500-1000mg if allergic**
- **Extra 3X3 guaze packs**
- **Frozen Gel Packs with Velco head wrap (www.cooljaw.com)**
- **Emergency call numbers!**
- **Post-op evening follow up call**
- **Generally follow up in one week**



1ST DAY

(0-24 Hours)

In order to assure that your recovery is as uneventful as possible, it is essential that you follow these instructions carefully:

DO: Apply ice to the operative site continuously to control any swelling and pain. (Even if no swelling or pain exists, these symptoms may appear 24-48 hours later.)

Bite on gauze for 20-30 minutes to control bleeding. (A slight ooze is normal for the first 2 days.) A moist tea bag is a good substitute for the first 2 days.

Take medications exactly as prescribed. Most medications are best taken with a full glass of water 30-60 minutes after a light meal.

DON'T: TOUCH OR DISTURB THE OPERATIVE SITE.

DON'T: SPIT.

DON'T: RINSE THE FIRST DAY

DON'T: SMOKE FOR 72 HOURS. (QUITTING WOULD BE EVEN BETTER.)

2ND DAY

(24-48 Hours)

DO: Begin salt water rinsing after every meal and at bedtime (1/2 tsp. of salt per quart of water.)

Rinse until clear.

Continue ice if swelling or pain exists.

(Black and bluish areas may appear following surgery. This is normal and should resolve in 1-2 weeks.)

Maintain good dietary intake-egg drinks, cereals, custard, mashed vegetables, chopped meat, soup, milk, stewed fruits, fruit juices, ice cream, milk shakes and popcicles.

IF NAUSEATED, TAKE FLAT GINGER ALE SLOWLY. (Shake out carbonation.)

OR

Take 2-4 Teaspoons of liquid Benadryl

3RD DAY

(and thereafter)

DO: Begin gentle stretching - open exercises.

Use syringe to aid in rinsing the operative site. (TIP SHOULD BE DIRECTLY OVER SOCKET OR INCISION.)

Begin applying moist heat to operative site.


Continue salt water rinses 4 times a day.


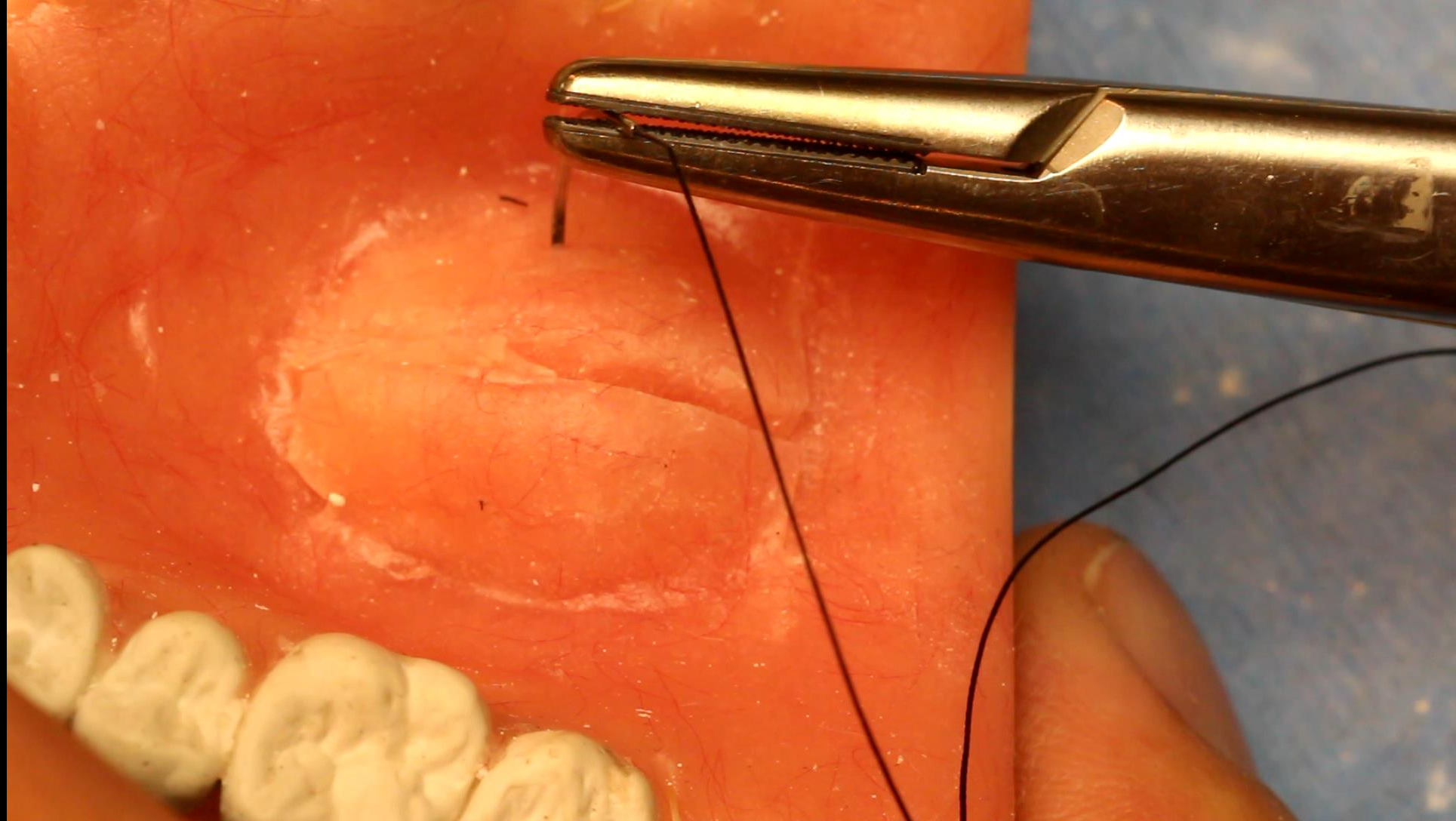
Pain pills may cause constipation. Use a mild laxative to maintain regularity. Drink plenty of water.

NOTE: Dry sockets may begin to appear. Increased pain, swelling and a foul taste and odor are the first symptoms.

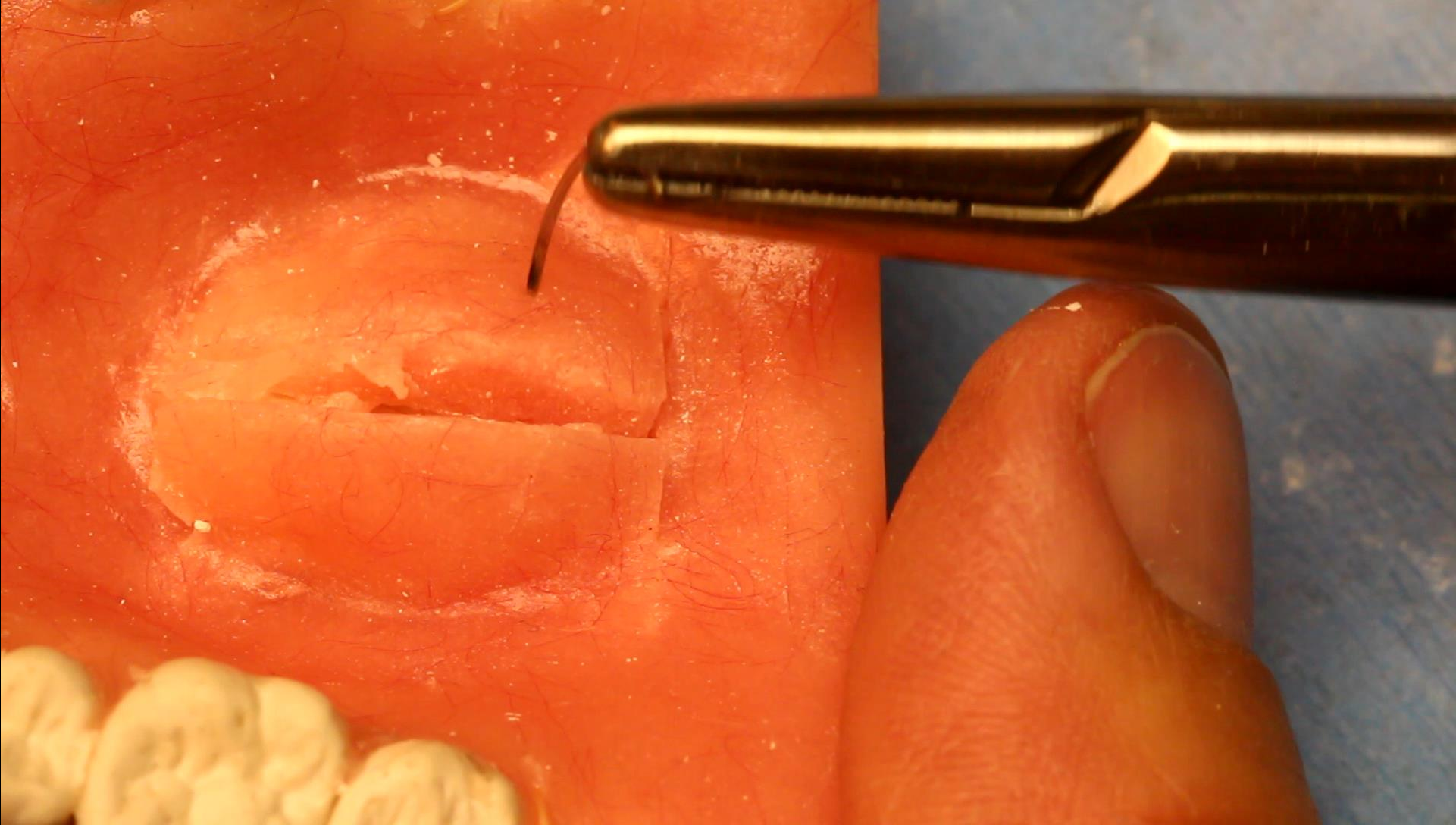
Clear (gut) stitches will dissolve within 3-5 days.

Average time to complete tissue healing/closure is approximately 3-6 weeks.





Vertical Mattress Suture



Inverted Mattress Suture